



Recurrent anterior shoulder instability Results of the glenoid based inferior capsular shift

Daniel V. C. STOFFELEN, Alope K. SINGHANIA, Jan MIEVIS, Peter REYNDERS

A total of forty consecutive patients suffering from recurrent traumatic anterior shoulder instability underwent stabilisation with a glenoid based inferior capsular shift. The patients were followed up prospectively by an independent observer (JM) using the Constant-Murley score and objective evaluation of shoulder movement and strength with an isometric dynamometer. The mean follow-up period was 50 months (range, 2 to 6.8 years). Three patients (7.5%) suffered a repeat, high energy, traumatic dislocation following an early return to sports activities. "Cybex" testing documented a minimal average loss of external rotation movement (4.4°) and strength (4.3%) with the arm in neutral, which was higher with the arm at 90° of abduction (i.e., 13.7° and 15.6%, respectively). The deficit in internal rotation strength was similarly lower in neutral position (2%), when compared to the deficit with the arm at 90° of abduction (13.5%). There was no measurable loss of internal rotation motion. Our study supports the use of a glenoid based inferior capsular shift, as there is a low recurrence rate and minimal deficit in shoulder movement and strength.

INTRODUCTION

Numerous operative techniques have been described in literature to deal with the frustrating problem of recurrent anterior glenohumeral instability.

Conventionally, open anterior stabilisation has been divided into soft tissue operations and bony procedures. The existence of a multitude of techniques, each with its own advantages and disadvantages, indicates a lack of consensus about an

acceptable gold standard, though Bankart's repair (4), first propounded in 1923, is quite popular. There has been past controversy between the advocates of procedures that limit external rotation, such as Putti-Platt (31) and Magnuson-Stack (28), and the proponents of an anatomical repair with the preservation of a better range of motion. Of late, there has been a swing towards the latter, because of suggestions that restricted abduction/external rotation could lead to the development of glenohumeral arthrosis (18, 19, 26, 36). There is evidence to suggest however, that recurrent pre-operative instability in itself could contribute to glenohumeral arthrosis, when stabilisation procedures are delayed (20). The high prevalence of recurrent anterior instability in young, high demand patients following a traumatic dislocation has also resulted in attempts at preserving a better range of movement to facilitate a return to full activity, including

From Diana, Princess of Wales, Hospital, Grimsby, U.K., St. Trudo Hospital, St Truiden, Belgium and University Hospital Gasthuisberg, Leuven, Belgium.

Daniel V. C. Stoffelen, MD, PhD, Consultant Orthopaedic Surgeon.

Alope K. Singhania, FRCS, Specialist Registrar.

Diana, Princess of Wales, Hospital, Grimsby, U.K.

Jan Mievis, MD, Orthopaedic Surgeon.

Regionaal Ziekenhuis St. Trudo, Stenaertstraat 3, B-3800 St. Truiden, Belgium.

Peter Reynders, MD, PhD, Clinical Head, Dept. of Traumatology.

University Hospital Gasthuisberg, B-3000 Leuven, Belgium.

Correspondence : Daniel V. C. Stoffelen, Bornestraat 172, 3012 Wilsele, Belgium. E-mail : dannystoffelen@aol.com.

© 2004, Acta Orthopædica Belgica.

sports. This has even lead to a move towards early arthroscopic stabilisation for the young, first-time traumatic dislocator, using staples (6, 8, 17, 25, 29, 34), bioabsorbable tacks (2, 10), transglenoid sutures (12, 15), suture anchors (15) or thermal capsular shrinkage. The results of these arthroscopic procedures have not, however, equalled those of the open operations, as most studies show a significantly higher failure rate (2, 3, 6, 8, 14, 17, 25, 29, 34, 40, 41, 46).

It is felt that an ideal stabilisation operation should be applicable in most patients with anterior instability, without being too demanding to perform technically. It should offer a low recurrence rate, while preserving full motion and strength to allow a return to the pre-injury levels of activity. In addition, it should not increase the long term risks of early onset arthritis due to alteration in the biomechanics of the shoulder joint. The mixed results reported by various studies to date demonstrate that this goal has not yet been achieved.

The purpose of the present study was to determine the long term results of the glenoid based inferior capsular shift. This procedure was used as it addresses both the Bankart lesion, caused by detachment of the antero-inferior capsulolabral complex and it rectifies the capsular laxity which invariably accompanies recurrent anterior instability. The operations were performed by one surgeon and the patients followed up prospectively by an independent observer, who assessed the functional outcome using the Constant-Murley score (7). The final range of movement and strength was documented using the "Isometric Dynamometer Cybex 350" (Lumex Inc.1982), which enabled an accurate and completely objective evaluation (22).

MATERIALS AND METHODS

Patient selection

Between January 1993 and December 1997, the senior author (D.V.C.S.) operated on 40 consecutive patients for recurrent unidirectional anterior instability. Patients with posterior instability, multidirectional instability or marked glenohumeral arthrosis were excluded for the purposes of this prospective study. None of the patients demonstrated any signs of hyperlaxity and the thumb-radius distance was within a range of 3 to 6 cen-

timetres for each patient. Of the forty patients studied, thirty-four were men and six were women. The average age was 27.4 years (range, 17 to 61 years). Eight patients had failure of previous surgery, three having had a Putti-Platt procedure and five an arthroscopic Bankart repair. All the patients related a history of a primary traumatic event followed by recurrent episodes of dislocation, with an average of 4.8 episodes (range, 2 to 30). They had failed to respond to a closely supervised regime of physiotherapy, consisting of glenohumeral and scapulothoracic muscle-strengthening exercises. There were no cases with a history of isolated subluxation without dislocation in this study.

Radiographic evaluation

Pre-operative anteroposterior, axillary and Stryker notch (15) radiographs were performed for all the shoulders. Each patient underwent a computerised tomography scan with intra-articular contrast medium (CT-arthrogram). A Bankart lesion was documented in all the forty patients (100%), while twenty-two patients (55%) demonstrated a clear Hill-Sachs lesion.

Examination under anaesthesia

This was performed with the patient supine to document the presence of anterior, posterior or inferior translation. Inferior translation was tested by the application of longitudinal traction while inspecting the acromiohumeral area for the appearance of a groove. Anterior and posterior translation was assessed with the limb abducted 90°, externally rotated 45° and slight axial compression of the humeral head into the glenoid. Anterior or posterior drawer was then used to confirm the presence of anterior or posterior laxity, respectively. None of the patients included in this study demonstrated posterior translation or evidence of multidirectional instability.

Operative procedure

A deltopectoral approach was used, retracting the cephalic vein laterally with deltoid muscle fibres. After incising the claviopectoral fascia and retracting the conjoint tendon medially, external rotation of the arm allowed a good exposure of the subscapularis tendon. The latter was split longitudinally along the length of its fibres, at the junction of the upper two-thirds and the lower one-third of the tendon. Splitting the subscapularis instead of dividing it, allows earlier rehabilitation

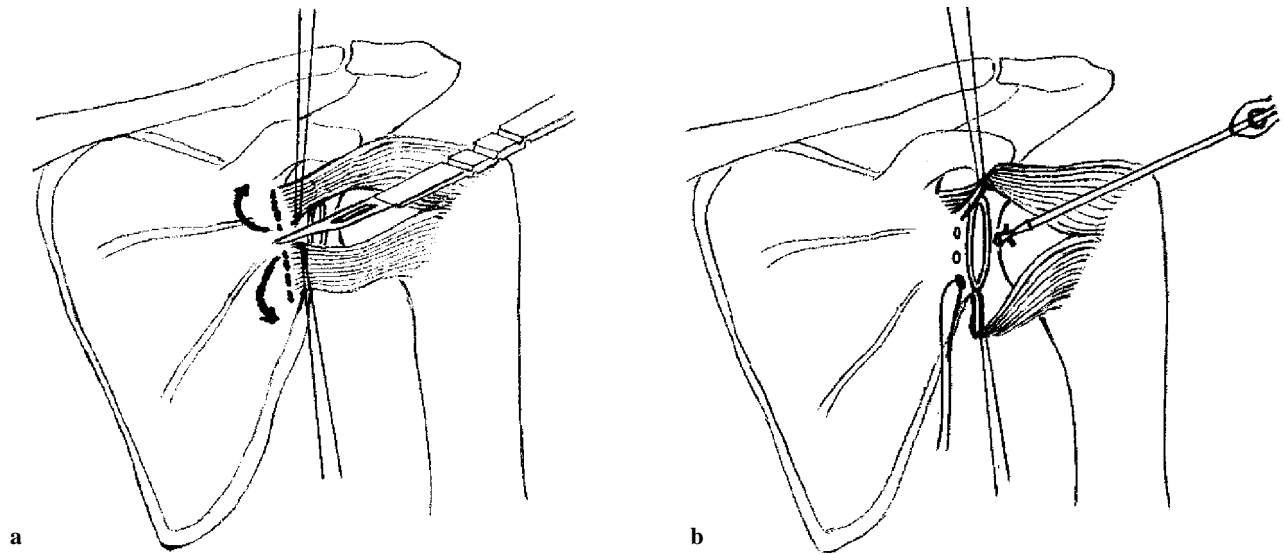


Fig. 1. — The glenoid based T-shaped inferior capsular shift ; **a.** — The glenoid based T-shaped capsular incision ; **b.** — The positioning of 3 Mitek anchors.

of subscapularis function (23). Once the anterior capsule was adequately exposed, a glenoid based T-shaped incision was made (fig 1a). The detached part of the antero-inferior capsulo-labral complex was identified and careful exposure of the glenoid rim was performed to its inferior extent. The anterior glenoid rim was roughened and three Mitek suture anchors (Mitek Products, Westwood, MA, U.S.A.) were placed at 6, 8 and 10 o'clock positions (fig 1b). The inferior capsular flap was first sutured on to the anchors, with the arm in a neutral position, i.e. without any abduction or external rotation. The superior capsular flap was then overlapped onto the inferior and sutured to the anchors at 8 o'clock and 10 o'clock positions. The degree of inferior capsular shift thus obtained was estimated in each case from the amount of overlap of the capsular flaps. This was found to be an average of 5 millimetres (range, 3 to 8) in the study sample.

Post-operative rehabilitation

The patient's operated shoulder was immobilised in an adduction sling for a period of three weeks. Gentle active-assisted range of motion exercises (90° abduction and forward elevation, without any external or internal rotation) were then initiated to begin mobilisation, followed by muscle strengthening exercises when the patient was able to perform the activities of daily living, usually at the six week stage. Concomitant abduction

and external rotation was discouraged for three months and the patient gradually returned to normal activity at the six month stage.

RESULTS

All the patients were followed up prospectively and assessed at a mean follow-up period of fifty months (range, 2 to 6.8 years). The Constant-Murley score was used to evaluate the clinical outcome of the procedure. This 100-point score assigns 15 points for pain, 20 points for activities of daily living, 40 points for range of movement and 25 points for power at 90° of abduction. The patients were examined by an independent observer (JM) and underwent "Cybex" testing to obtain an objective record of the range of movement and strength when compared to the normal shoulder (table I). Additional questions were asked about the level of patient satisfaction, the subjective feeling of instability or apprehension, the extent of participation in work and sports and whether the patient had sustained a subluxation or dislocation following surgery. Clinical examination was done to test for the presence of apprehension.

Of the forty patients in the study, none complained of any pain or subjective sense of instability,

Table I

Number of patients	40 (100%)
Return to pre-injury occupation	37 (92.5%)
Return to pre-injury sporting activities	35 (87.5%)
Recurrent dislocation	3 (7.5%)
Apprehension	0
Re-operation	1 (2.5%)
Constant-Murley score	90.87 (80 to 98)
Average deficit in range of motion compared to normal shoulder (<i>degrees</i>)	
External rotation at side	4.4° (0° to 12°)
External rotation at 90° abduction	13.7° (5° to 23°)
Internal rotation at side	0°
Internal rotation at 90° abduction	0°
Average deficit in strength compared to normal shoulder	
External rotation at side - at 60 speed	4.3%
- at 240 speed	3.8%
External rotation at 90° abduction - at 60 speed	15.6%
- at 240 speed	11 %
Internal rotation at side - at 60 speed	2 %
- at 240 speed	5.5%
Internal rotation at 90° abduction - at 60 speed	13.5%
- at 240 speed	16.5%

post-operatively. Three patients (7.5%) gave a history of mild limitation in their ability to perform heavy manual activity, leading to a change of occupation. Two patients (5%) described a mild restriction in their sports activities, while four patients (10%) reduced their sports activities voluntarily. There was no deficit in the range of forward elevation, abduction or internal rotation in any of the patients, though most demonstrated some limitation of external rotation, which was more evident at 90° of abduction (Table 1). None of the patients suffered axillary nerve damage, infection or scar problems, barring a hypertrophic scar without any aesthetic concern in five patients (12.5%).

Analysis of failures

Three male patients (7.5%) suffered a repeat traumatic episode in the follow-up period, leading to a dislocation of the operated shoulder. Two of these patients had a history of a failed stabilisation procedure prior to their inferior capsular shift, one a Putti-Platt (31) operation and the other an arthro-

scopic Bankart repair. All three patients (aged 18, 19 and 31, respectively) had pre-operative evidence of a Hill-Sachs lesion with three or more dislocations each, but had obtained a good result initially, returning quickly to their previous level of sports activities. This, we feel, resulted in these three cases in a traumatic event of sufficient severity to have caused dislocation of a normal shoulder. The mechanism of injury in each case was a fall, combined with a severe abduction-external rotation force. The first patient slipped while carrying a tree on the operated shoulder, the second patient was gliding down a slope during a mountain climbing exercise holding on with the operated arm and in case of the third patient a footballer landed on his stabilised shoulder in a football game.

Of the above, one patient sustained severe damage to the anterior rim of the glenoid and subsequently underwent a Bristow procedure. He did not experience any further problems on follow-up. The other two did not have any limitation in daily activities and elected to reduce their sporting commitments rather than undergo revision surgery. They did not develop subjective instability, so were treated expectantly.

DISCUSSION

The present study stresses the need for addressing both the aetiological factors contributing to recurrent anterior instability, namely the antero-inferior capsulo-labral detachment and the capsular laxity, by combining labral reattachment with a glenoid based inferior capsular shift. Many studies have reported recurrence rates of 3 to 9% after open reconstruction (1, 9, 21, 23, 30, 32, 37, 38, 39, 47), while the reviews of arthroscopic stabilisation demonstrate a substantially higher failure rate between 14 to 49% (13, 24, 35, 43, 45, 49). Some studies that compare these two techniques (11, 12, 15, 42) again show significant benefits in performing open repair over arthroscopic Bankart repair, as the latter, we feel, cannot rectify capsular laxity to any appreciable degree. In our opinion, an arthroscopic technique imparts no additional benefit to the patient, when compared to the versatility of an open anatomical approach to the shoulder using the

subscapularis split, as described in our study. The relatively high recurrence rate of 7.5% in our series is attributable to the fact that the patients recovered an excellent range of movement, with early return to contact sports, predisposing them to repeat high energy trauma.

Various studies have documented that limited range of motion and reduced strength after stabilisation surgery affects return to work, curtails sports activities at a competitive level (5) and can even precipitate earlier onset of glenohumeral arthritis (18, 19, 26, 36). Our study evaluates the range of motion and strength using Cybex testing, thus eliminating observer error. There was minimal loss of external rotation movement and strength with the arm at the side, when compared to the contralateral side, though the deficit with the arm abducted 90° was significantly higher. However our findings when compared to those of similar studies evaluating the Bankart repair (27, 36) or the Bristow procedure (44), provide justification for recommending the glenoid based inferior capsular shift for recurrent anterior instability.

The limitation of this study is that it is not a randomised comparison of two treatment methods, nor does it allow conclusions to be drawn about the long term risk of developing glenohumeral arthritis. However, as the latter has been related to motion loss, which has been minimal in our study sample, we conclude that an anatomical approach for reconstruction using the glenoid based inferior capsular shift with a subscapularis split, can be recommended as the optimal stabilisation operation. This will also enable later salvage surgery, should it become necessary in a small proportion of patients, without any additional difficulties, as the normal anatomy has been fully preserved.

REFERENCES

1. **Altchek DW, Warren RF, Skyhar MJ, Ortiz G.** T-plasty modification of the Bankart procedure for multidirectional instability of the anterior and inferior types. *J Bone Joint Surg* 1991 ; 73-A : 105-112.
2. **Arciero RA, Taylor DC, Snyder RJ, Uhorchak JM.** Arthroscopic bioabsorbable tack stabilization of initial anterior shoulder dislocations : a preliminary report. *Arthroscopy* 1995 ; 11 : 410-417.
3. **Bacilla P, Field LD, Savoie FH III.** Arthroscopic Bankart repair in a high demand patient population. *Arthroscopy* 1997 ; 13 : 51-60.
4. **Bankart A.** Recurrent or habitual dislocation of the shoulder-joint. *BMJ* 1923 ; 1132-1133.
5. **Bigliani LU, Kurzweil PR, Schwartzbach CC, Wolfe IN, Flatow EL.** Inferior capsular shift procedure for anterior-inferior shoulder instability in athletes. *Am J Sports Med* 1994 ; 22 : 578-584.
6. **Burger RS, Shengel D, Bonatus T, Lewis J.** Arthroscopic staple capsulorrhaphy for recurrent shoulder instability. *Orthop Trans* 1990 ; 14 : 596-597.
7. **Constant CR, Murley AHG.** A clinical method of functional assessment of the shoulder. *Clin Orthop* 1987 ; 214 : 160-4.
8. **Coughlin L, Rubinovich M, Johansson J, White B, Greenspoon J.** Arthroscopic staple capsulorrhaphy for anterior shoulder instability. *Am J Sports Med* 1992 ; 20 : 253-256.
9. **Dickson JW, Devas MB.** Bankart's operation for recurrent dislocation of the shoulder. *J. Bone Joint Surg* 1957 ; 39-B : 114-119.
10. **Dora C, Gerber C.** Shoulder function after arthroscopic anterior stabilization of the glenohumeral joint using an absorbable tac. *J Shoulder Elbow Surg* 2000 ; 9 : 294-298.
11. **Field L, Savoie F, Griffith P.** A comparison of open and arthroscopic Bankart repair [abstract]. *J Shoulder Elbow Surg* 1999 ; 8 : 195.
12. **Geiger DF, Hurley JA, Tovey JA, Rao JP.** Results of arthroscopic versus open Bankart suture repair. *Clin Orthop* 1997 ; 337 : 111-117.
13. **Grana WA, Buckley PD, Yates CK.** Arthroscopic Bankart suture repair. *Am J Sports Med* 1993 ; 21 : 348-353.
14. **Gross RM.** Arthroscopic shoulder capsulorrhaphy : does it work ? *Am J Sports Med* 1989 ; 17 : 495-500.
15. **Guanche CA, Quick DC, Sodergren KM, Buss DD.** Arthroscopic versus open reconstruction of the shoulder in patients with isolated Bankart lesions. *Am J Sports Med* 1996 ; 24 : 144-148.
16. **Hall RH, Isaac F, Booth CR.** Dislocations of the shoulder with special reference to accompanying small fractures. *J Bone Joint Surg* 1959 ; 41-A : 489-494.
17. **Hawkins RB.** Arthroscopic stapling repair for shoulder instability : a retrospective study of 50 cases. *Arthroscopy* 1989 ; 5 : 122-128.
18. **Hawkins RH, Hawkins RJ.** Failed anterior reconstruction for shoulder instability. *J Bone Joint Surg* 1985 ; 67-B : 709-714.
19. **Hawkins RJ, Angelo RL.** Glenohumeral osteoarthritis. A late complication of the Putti-Platt repair. *J Bone Joint Surg* 1990 ; 72-A : 1193-1197.
20. **Hindmarsh J, Lindberg A.** Eden-Hybbinette's operation for recurrent dislocation of the humero-scapular joint. *Acta Orthop Scand* 1967 ; 38 : 459-478.

21. **Hovellius L.** Anterior dislocation of the shoulder in teenagers and young adults : five year prognosis. *J Bone Joint Surg* 1987 ; 69-A : 393-399.
22. Isolated joint testing and exercise : a handbook for using Cybex II and the UBXT. *Lumex Inc.* 1982.
23. **Jobe FW, Giangarra CE, Kvitne RS, Glousman RE.** Anterior capsulolabral reconstruction of the shoulder in athletes in overhead sports. *Am J Sports Med* 1991 ; 19 : 428-434.
24. **Landsiedl F.** Arthroscopic therapy of recurrent anterior luxation of the shoulder by capsular repair. *Arthroscopy* 1992 ; 8 : 296-304.
25. **Lane JG, Sachs RA, Riehl B.** Arthroscopic staple capsulorrhaphy : a long term follow-up. *Arthroscopy* 1993 ; 9 : 190-194.
26. **Lusardi DA, Wirth MA, Wurtz D, Rockwood CA Jr.** Loss of external rotation following anterior capsulorrhaphy of the shoulder. *J Bone Joint Surg* 1993 ; 75-A : 1185-1192.
27. **Magnusson L, Kartus J, Ejerhed L, Hultenheim I, Sernert N, Karlsson J.** Revisiting the open Bankart experience : a four- to nine-year follow-up. *Am J Sports Med* 2002 ; 30 : 778-782.
28. **Magnuson P, Stack J.** Recurrent dislocation of the shoulder. *JAMA* 1943 ; 123 : 889-892.
29. **Matthews LS, Vetter WL, Oweida SJ, Spearman J, Helfet DL.** Arthroscopic staple capsulorrhaphy for recurrent anterior shoulder instability. *Arthroscopy* 1988 ; 4 : 106-111.
30. **Neer CS, Foster CR.** Inferior capsular shift for involuntary inferior and multidirectional instability of the shoulder. *J Bone Joint Surg* 1980 ; 62-A : 897-908.
31. **Osmond-Clarke H.** Habitual dislocation of the shoulder : the Putti-Platt operation. *J Bone Joint Surg* 1948 ; 30-B : 19-25.
32. **Pagnani MJ, Dome DC.** Surgical treatment of traumatic anterior shoulder instability in american football players. *J Bone Joint Surg* 2002 ; 84-A : 711-715.
33. **Pollock RG, Owens JM, Nicholson GP, Weinstein DM, Duralde XA, McIveen SJ, Flatow EL, Bigliani LU.** The anterior inferior capsular shift procedure for anterior glenohumeral instability : technique and long-term results. *Orthop Trans* 1993-1994 ; 17 : 1109.
34. **Rao JP, Tovey JE, Zoppi A, Implicato D, Mastro Monaco E, D'Ascoli B, Miller SS.** Comparison of arthroscopic capsulorrhaphy for anterior shoulder instability : stapling versus suturing. *Orthop Trans* 1993-1994 ; 17 : 972-973.
35. **Roberts SN, Taylor DE, Brown JN, Hayes MG, Saies A.** Open and arthroscopic techniques for the treatment of traumatic anterior shoulder instability in Australian rules football players. *J Shoulder Elbow Surg* 1999 ; 8 : 403-9.
36. **Rosenberg BN, Richmond JC, Levine WN.** Long-term followup of Bankart reconstruction : incidence of late degenerative glenohumeral arthrosis. *Am J Sports Med* 1995 ; 23 : 538-544.
37. **Rowe CR, Patel D, Southmayd WW.** The Bankart procedure. A long-term end-result study. *J Bone Joint Surg* 1978 ; 60-A : 1-16.
38. **Rowe CR, Zarins B.** Recurrent transient subluxation of the shoulder. *J Bone Joint Surg* 1981 ; 63-A : 863-872.
39. **Rubenstein D, Jobe F, Glousman R.** Anterior capsulolabral reconstruction of the shoulder in athletes. *J Shoulder and Elbow Surg* 1992 ; 1 : 229-237.
40. **Sperber A, Hamberg P, Karlsson J, Sward L, Wredmark T.** Comparison of an arthroscopic and an open procedure for posttraumatic instability of the shoulder : a prospective, randomized multicenter study. *J Shoulder Elbow Surg* 2001 ; 10 : 105-108.
41. **Stein DA, Jazrawi L, Bartolozzi AR.** Arthroscopic stabilization of anterior shoulder instability : a review of the literature. *Arthroscopy* 2002 ; 18(8) : 912-924.
42. **Steinbeck J, Jerosch J.** Arthroscopic transglenoid stabilization versus open anchor suturing in traumatic anterior instability of the shoulder. *Am J Sports Med* 1998 ; 26 : 373-378.
43. **Torchia ME, Caspari RB, Asselmeier MA, Beach WR.** Arthroscopically assisted transglenoid suture repair for anterior instability : 2-8 year results in 150 shoulders [Abstract]. *Orthop Trans* 1996 ; 20 : 79.
44. **Torg JS, Balduini FC, Bonci C et al.** A modified Bristow-Helfet-May procedure for recurrent dislocation and subluxation of the shoulder : report of two hundred and twelve cases. *J Bone Joint Surg* 1987 ; 69-A : 904-913.
45. **Walch G, Boileau P, Levigne C, Mandrino A, Neyret P, Donell S.** Arthroscopic stabilization for recurrent anterior shoulder dislocation : results of 59 cases. *Arthroscopy* 1995 ; 11 : 173-179.
46. **Wheeler JH, Ryan JB, Arciero RA, Molinari RN.** Arthroscopic versus nonoperative treatment of acute shoulder dislocation in young athletes. *Arthroscopy* 1989 ; 5 : 213-217.
47. **Wirth MA, Blatter G, Rockwood CA Jr.** The capsular imbrication procedure for recurrent anterior instability of the shoulder. *J Bone Joint Surg* 1996 ; 78-A : 246-259.
48. **Yee AJ, Devane PA, Horne G.** Surgical repair for recurrent anterior instability of the shoulder. *Aust N Z J Sur.* 1999 ; 69 : 802-807.
49. **Youssef JA, Carr CF, Walther CE, Murphy JM.** Arthroscopic Bankart suture repair for recurrent traumatic unidirectional anterior shoulder dislocations. *Arthroscopy* 1995 ; 11 : 561-563.