



Bilateral pisiform-hamate coalition causing carpal tunnel syndrome and tendon attrition A case report

Ioannis TSIONOS, Jean-Luc DRAPÉ, Dominique LE VIET

Congenital coalition of pisiform and hamate is rare and had been considered asymptomatic in the first reports. The authors report a case of bilateral pisiform-hamate coalition in a young patient, causing symptoms of median nerve compression in the carpal tunnel and attritional changes on digital flexor tendons. This type of coalition had not previously been related to such symptoms. Additionally, the morphology of the coalition on the right side is unique among published cases. Surgical treatment with bilateral excision of the coalition resulted in the resolution of symptoms.

INTRODUCTION

Coalition of carpal bones may be an incidental radiological finding and some reports resulted from anthropologic surveys.

The most common type of carpal coalition is between the lunate and triquetral bones. Isolated coalitions between the pisiform and the hamate have rarely been reported and only recently has their presence been related to symptoms.

This is a case of a bilateral pisiform-hamate coalition in a young white woman, reported as the first such coalition causing symptoms of median nerve compression in the carpal tunnel and affecting digital flexor tendons.

CASE REPORT

A 29-year-old right-handed white woman, who was a veterinarian, was referred because of a three-

month history of numbness and paraesthesias with a median nerve distribution in both hands, mostly manifesting after physical effort. Symptoms were more intense on the right side and became almost permanent over the last 15 days. There was no history of trauma in her medical record.

Physical examination revealed tenderness upon palpation of both hypothenar eminences. The patient also experienced pain when flexing the little finger against resistance.

Plain radiographs revealed a bilateral pisiform-hamate coalition (fig 1).

Electromyographic study revealed compression of the median nerve bilaterally, with changes in sensitive potentials and conduction velocities, and bilateral signs of slight denervation of the abductor pollicis brevis muscle.

A further investigation using CT scan with 3D-reconstruction disclosed the exact morphologic nature of these coalitions (fig 2, 3). On the right side, there was a coalition between the pisiform and the terminal part (beak) of the hook of the

From Institut de la Main and Hôpital Cochin, Paris, France.

Ioannis Tsionos, MD, Fellow.

Dominique Le Viet, MD, Consultant Orthopaedic Surgeon.

Institut de la Main, Paris, France.

Jean-Luc Drapé, MD, Consultant Radiologist.

Radiologic Department, Hôpital Cochin, Paris, France.

Correspondence : Dominique Le Viet, Institut de la Main, Clinique Jouvenet, 6, square Jouvenet, 75016 Paris, France.
E-mail : family.lv@noos.fr.

© 2004, Acta Orthopædica Belgica.

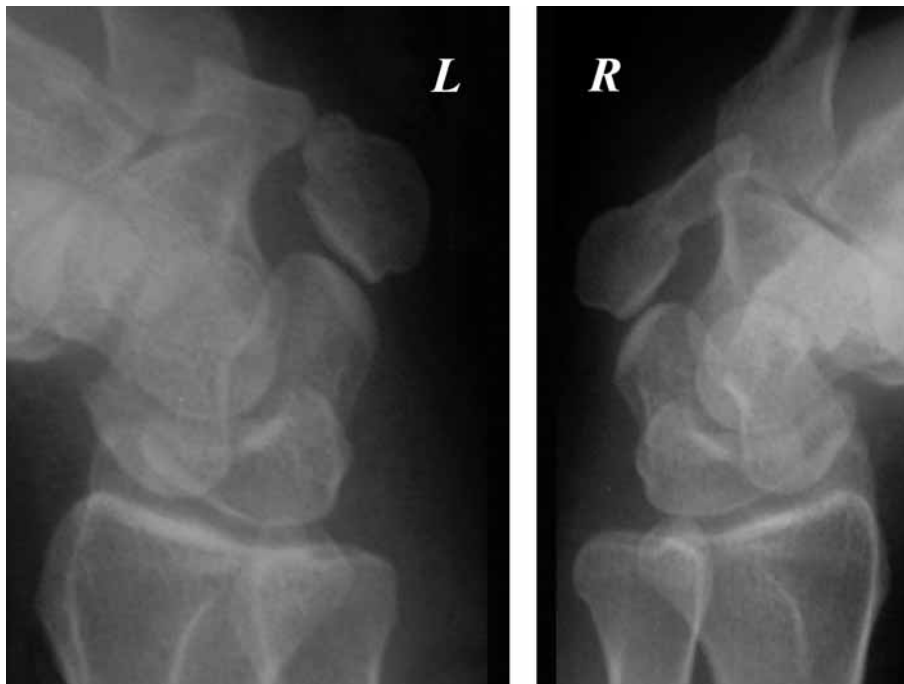


Fig. 1. — Oblique radiographs of both wrists showing the morphology of the pisohamate coalition on both sides (R : right wrist, L : left wrist).

hamate ; both appeared as a single bone block with its largest part situated proximally ; its long axis was positioned at some 50° in relation to the long axis of the 3rd metacarpal, in the frontal plane. The base of the hook of the hamate remained in continuity with the body of the bone but formed what appeared to be a synchondrosis with the osseous block described above. On the left side, the anatomic anomaly was different : the hook of the hamate was voluminous and its terminal part was abnormally enlarged, articulating with an abnormal process of the pisiform bone. The triquetral-pisiform joint on both sides appeared normal. In contrast, the abnormal synchondroses described above presented very narrow joint lines.

Magnetic resonance imaging revealed that the content of both carpal tunnels was tightly packed at the level of the distal margin of the transverse carpal ligament. Especially on the right side (fig 4), the voluminous block pisiform-hook of hamate appeared to reduce the diameter of the carpal tunnel and exert pressure onto the ulnar digital flexor tendons.

Conservative treatment with immobilisation of the hand and non-steroidal anti-inflammatory medication failed to substantially alleviate the symptoms.

Four months after onset of the symptoms, the patient had a surgical exploration on the right, by the senior surgeon (DLV). Under axillary anaesthesia and tourniquet control, with a transverse incision at the level of the distal palmar wrist crease, prolonged longitudinally to the third intermetacarpal space distally and along the radial border of the tendon of flexor carpi ulnaris proximally, the carpal tunnel as well as Guyon's tunnel were approached and opened. Proximally, the ulnar nerve was situated radially to the pisiform ; it was then found riding over the pisiform-hook of hamate block, thus passing ulnarly to the base of the hook of the hamate (fig 5). The pisiform-hook of hamate block presented considerable mobility and was deprived of ligamentous attachments (piso-hamate or piso-metacarpal). Thus, preserving the pisiform was considered illusory and a subperiosteal excision of the whole block was performed. It was then

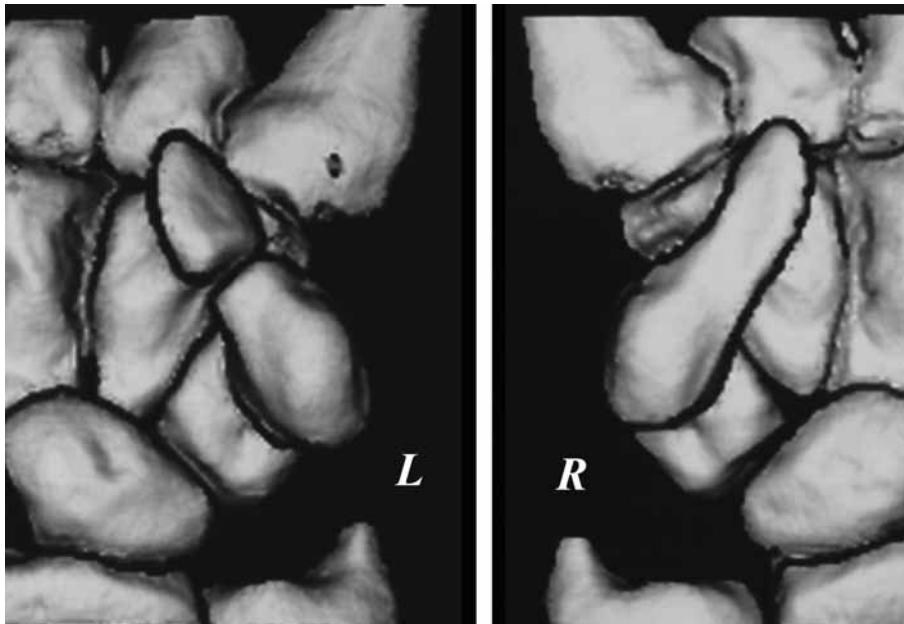


Fig. 2. — 3D-reconstruction view of the anterior aspect of both wrists preoperatively, based on CT-scan cuts. On the right side, the coalition took the form of a continuous osseous bar.

noted that, at the level of the synchondrosis between the block and the base of the hamate hook, there was an erosion of the flexor digitorum profundus tendon to the little finger. The remainders of the base of the hamate hook were removed and a synovectomy of the flexor tendon was done. Finally, the flexor carpi ulnaris tendon insertion was fixed onto the fascia of the adjacent hypothenar muscles with absorbable sutures.

Five months after the onset of symptoms, the patient was operated on her left side. The ulnar nerve was again found riding over the junction between the pisiform and hamate hook. The hypertrophic hamate hook was totally excised subperiosteally, along with its synchondrosis with the pisiform and with the anomalous process of the pisiform protruding towards the hook of the hamate. The pisiform was stabilised by suturing its periosteal envelope to adjacent tissues. Another finding was a palmaris longus muscle with a muscle belly situated inside the carpal tunnel and a double insertion onto the tunnel's roof; this muscle was excised.

On both sides, postoperative aftercare consisted of a three-week immobilisation period and active assisted physiotherapy thereafter.

The patient was reviewed 17 months after the second operation. She had been completely free of symptoms on the right side by the second postoperative month. On the left side, there was still some dull pain over the ulnar part of the palm, appearing mostly after manual effort. Electromyographic study showed complete remission of pre-operative findings on both sides. A repeat CT scan was then performed. On transverse cuts through the left triquetral-pisiform joint, signs of arthritis were seen on its radial border, with some irregularity of the pisiform's subchondral bone plate and an incipient osteophyte. The patient considers her symptoms as minimal and no further treatment is planned at the moment.

DISCUSSION

Carpal coalitions can be either isolated anomalies or a manifestation of a generalised disease,

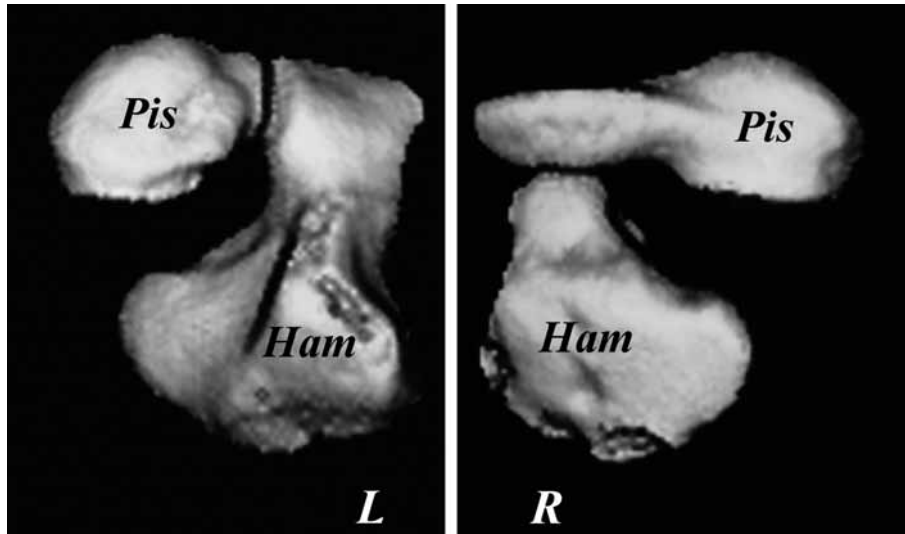


Fig. 3. — A special preoperative 3D-reconstruction view isolating carpal bones implicated in the coalition (pis : pisiform, ham : hamate).

possibly combined with extraskelatal disorders (8). It is generally considered that coalitions associated with generalised disorders are often multiple and extend across carpal rows (8). The incidence of carpal coalitions altogether was found to be around 0.7% in English schoolchildren (5), and much more frequent in some African populations (2, 7). The commonest is lunotriquetral coalition.

Minnaar de Villiers (7) classified lunotriquetral coalitions into four radiological types (table I). This classification may be applicable to other carpal coalitions as well.

Pisiform-hamate coalition was first described as an asymptomatic finding from radiological surveys, with familial tendency (2, 3).

Two cases of symptomatic pisiform-hamate coalition were first reported by Ganos and Imbriglia (4), the first such coalitions observed in white subjects. Both cases presented with local pain.

Berkowitz *et al* (1) described two cases of pisiform-hamate coalition in which symptoms came from ulnar nerve compression at the coalition site.

The case presented above is the first report relating this very rare coalition to median nerve compression in the carpal tunnel and to attrition of finger flexor tendons. The bone bar present on the

right and the hypertrophic hamate hook on the left caused both median nerve compression and erosion of flexor digitorum profundus to the little finger. The presence of an aberrant muscle may have contributed to nerve compression on the left. The coalition in our case was type 1 on the left (resembling pseudarthrosis); on the right, the coalition was type 3 (complete fusion) with additionally a synchondrosis between the bone block pisiform-hamate hook and the base of the hamate hook. To the best of our knowledge, this pattern had never been described before : the block pisiform-hamate hook “detached”, in some way, the hook from the

Table I. — Types of carpal coalitions in relation to their radiological appearance (according to Minnaar’s classification)

| Radiological Types of Carpal Coalitions | Radiological Appearance |
|---|--|
| Type 1 | Incomplete fusion resembling pseudarthrosis |
| Type 2 | Partial osseous fusion with notch of varying depth |
| Type 3 | Complete fusion |
| Type 4 | Complete fusion with other carpal anomalies |

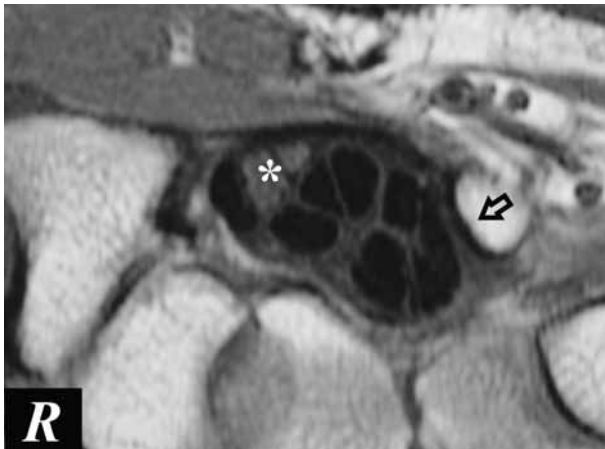

Fig. 4. — Transverse MRI-scan cut at the level of the distal margin of the carpal tunnel, on the right. Note compression exercised by the distal part of the coalition bone block (arrow) on the most ulnar flexor digitorum profundus tendons. Asterisk indicates position of median nerve.

body of the hamate. An explanation to this may be the independent ossification of the hook in the form of an os hamuli proprium (6), which then progressively fused with the pisiform into a continuous bone block.

Based on the assumption that a grossly unstable pisiform on the right would lead to piso-triquetral osteoarthritis, we excised it (together with the osseous bar) and we conserved it on the left. In fact, the patient is now mildly symptomatic on the left side. Retrospectively, reconstruction of pisiform ligamentous attachments on the left may not have sufficed to stabilise it, and thus arthritis ensued. Certainly, should the cartilage of the pisotriquetral joint be damaged pre-operatively, one should rather consider excising the pisiform with the coalition (4).

Joints begin to shape soon after formation of cartilaginous centres for bones, which takes place in the sixth week of gestation. An intermediate zone consisting of three layers will give rise to articular cartilage and, by autolysis of the central layer, to the joint cavity. Congenital carpal coalitions are believed to be the result of a failure of segmentation at the level of a future intercarpal joint (9). Thus, initially a cartilaginous bridge persists,

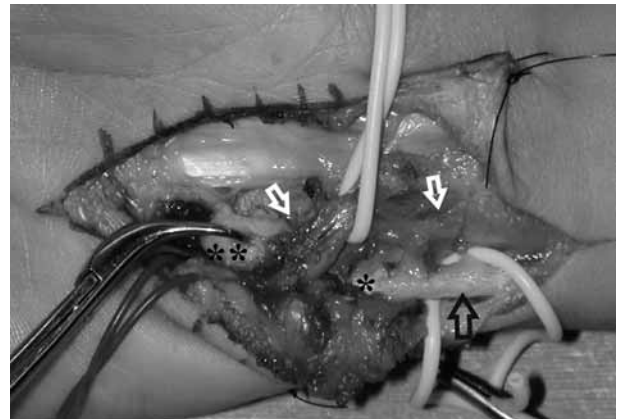


Fig. 5. — Right hand, intraoperative photograph (distal is on the left). Black arrow shows tendon of flexor carpi ulnaris. The proximal (*) as well as the distal (***) part of the pisiform-hamate coalition is visible. The ulnar nerve and vessels override it, on passing from the forearm to the hypothenar region (white arrows).

which may then be subject to partial or complete ossification (5), during the first years of life (2) or later in adolescence (3). Nevertheless, two ossification centres are established, each in each carpal bone, independently of the presence and size of the cartilaginous bridge (5). Different radiological types of coalition encountered in adults may thus be explained by different degrees of progression in antenatal segmentation and postnatal ossification processes. However, the above mechanism cannot be applied to pisohamate coalitions, because these two bones do not form a cartilaginous block before segmentation. Cartilaginous metaplasia of the pisohamate ligament could be a plausible reason (3).

We found it appropriate to report this bilateral case of congenital pisohamate coalition because of its rarity, its relation to symptoms of carpal tunnel syndrome and attritional changes of finger flexor tendons and finally because on the right side it took a *forme fruste* never described before.

REFERENCES

1. Berkowitz AR, Melone CP Jr, Belsky MR. Pisiform-hamate coalition with ulnar neuropathy. *J Hand Surg* 1992 ; 17-A : 657-662.

2. **Cockshott WP.** Carpal fusions. *AJR* 1963 ; 89 : 1260-1271.
3. **Cockshott WP.** Pisiform hamate fusion. *J Bone Joint Surg* 1969 ; 51-A : 778-780.
4. **Ganos DL, Imbriglia JE.** Symptomatic congenital coalition of the pisiform and hamate. *J Hand Surg* 1991 ; 16-A : 646-650.
5. **Hughes PCR, Tanner JM.** Development of carpal bone fusions as seen in serial radiographs. *Br J Radiol* 1966 ; 39 : 943-949.
6. **Keats TE, Anderson MW.** *Atlas of Normal Roentgen Variants that may Simulate Disease.* Mosby, St. Louis, Seventh edition, 2001, pp 539-612.
7. **Minnaar de Villiers AB.** Congenital fusion of the lunate and triquetral bones in the South African Bantu. *J Bone Joint Surg* 1952 ; 34-B : 45-48.
8. **Poznanski AK, Holt JF.** The carpals in congenital malformation syndromes. *AJR* 1971 ; 112 : 443-459.
9. **Resnik CS, Grizzard JD, Simmons BP, Yaghami I.** Incomplete carpal coalition. *AJR* 1986 ; 147 : 301-304.