

# Autologous bone plug-sliding with core decompression and bone marrow aspirate concentrate application: a joint-preserving surgical technique for corticosteroid-induced osteonecrosis of femoral head

C.D. DAVULCU<sup>1</sup>, B. KARAIMAİLOĞLU<sup>1</sup>, M.K. OZSAHİN<sup>1</sup>, E. DAVUTLUOĞLU<sup>1</sup>, D. AKBABA<sup>1</sup>, E. TERZİ<sup>2</sup>, M.C. ÜNLÜ<sup>1</sup>

<sup>1</sup>Istanbul University Cerrahpasa Medical School, Department of Orthopedics and Traumatology, Istanbul, Turkey; <sup>2</sup>Avcular Hospital, Istanbul, Turkey.

Correspondence at: Bedri Karaismailoğlu, Istanbul University-Cerrahpasa, Cerrahpasa Medical School, Department of Orthopedics and Traumatology, Istanbul, Turkey, Tel: +90 537 415 4109, Email: bedrikio@hotmail.com

**This study aimed to describe a surgical procedure for the management of corticosteroid-induced osteonecrosis of the femoral head (ONFH) and report its clinical results. The technique included harvesting a bone plug from the lateral femoral neck, core decompression, and bone marrow aspirate concentrate (BMAC) application; the procedure was completed by press-fit insertion of the autologous bone plug in the debrided area. Autologous bone plug-sliding with core decompression and bone marrow concentrate aspirate application provides good clinical outcomes in the management of ONFH. A retrospective review was performed using records of patients operated on between October 2019 and June 2021. Only patients with Ficat-Arlet stage-2 ONFH, who underwent the procedure described, were included. Twenty-nine hips (18 patients) were included and evaluated clinically and radiologically. Clinical evaluation included the Harris hip score (HHS) and Visual analogue scale (VAS) for pain, while radiological evaluation included direct radiographs. The average age was 39.8 years ( $\pm 11.7$ , range: 24-65 years). The average follow-up was 13.5 months ( $\pm 3.4$ , range: 8-19 months). There were improvements in the VAS pain and Harris hip scores in all patients. Average HHS increased from 61.90 to 87.45 ( $p < 0.001$ ), while the average VAS pain score decreased from 7.14 to 3.27 ( $p < 0.001$ ). No complications were encountered in any of the patients during the follow-up. None of the patients had femoral head collapse on the latest radiograph or required total hip replacement. The combination of the novel autologous bone plug-sliding method with conventional regenerative methods is a successful treatment choice for ONFH.**

## INTRODUCTION

Corticosteroid-induced osteonecrosis of the femoral head (ONFH) is a debilitating condition that primarily affects younger, active individuals. Corticosteroid use is the most common cause of ONFH, and the stage at diagnosis is earlier than in other groups<sup>20</sup>. Corticosteroids are widely used in the treatment of various disorders, including severe acute respiratory syndrome (SARS)<sup>1</sup>. Their usage has increased greatly during the current COVID-19 outbreak because there is evidence that dexamethasone may decrease mortality, especially in moderate-to-severe acute respiratory distress syndrome caused by SARS-CoV-2 infection<sup>19</sup>. However, the increased use of systemic corticosteroids is also associated with the increased incidence of serious adverse events, including ONFH<sup>25</sup>.

In pre-collapse ONFH patients, joint-preserving surgical techniques, such as core decompression, autograft application, and cell-based therapies (PRP,

stem cell, etc.) are preferred<sup>5</sup>. Success rates up to 94% have been reported in the pre-collapse stage with these treatments<sup>9</sup>. Since core decompression alone might be insufficient for new bone formation, the results are often unsatisfactory<sup>12</sup>. However, more efficient techniques are being investigated and combination strategies, such as core decompression and autografts (C+A), core decompression and stem cells (C+S), etc., are being developed<sup>5</sup>. However, these techniques also possess some disadvantages. C+A causes donor site morbidity, while C+S lacks structural support, and stem cells can leak from the area of application.

In this study, we report the clinical outcomes of pre-collapse corticosteroid-induced ONFH patients treated with a combination of autologous bone plug-sliding and stem cell therapy. This technique does not only prevent donor site morbidity and loss of healthy bone but also provides structural support and prevents stem-cell leakage. To our knowledge, this is the first study to present clinical results of an autologous bone plug-

sliding technique with core decompression and bone marrow aspirate concentrate (BMAC) application in early-stage corticosteroid-induced ONFH patients.

This study aims to find out the answer to the question: “Does autologous bone plug-sliding technique with core decompression and bone marrow aspirate concentrate provide good clinical outcome in the management of ONFH?” We hypothesized that the described technique yields successful clinical outcome.

## MATERIALS AND METHODS

All procedures were scheduled in the inpatient operative setting and were operated under general anesthesia by the author (MCU). A single dose of second-generation cephalosporin was administered intravenously at induction. We routinely used chemical thromboprophylaxis for 7 days in all cases. Blood

transfusions were not required in any case. Standard skin preparation and sterilization were performed. The patients were placed supine on a radiolucent traction table, and the iliac wing and hip were covered in a sterile manner.

Cancellous bone was obtained through spina iliaca anterior superior using an anticoagulant-coated trocar (Argon®, 11 g, 3 + 2 holes). Bone marrow aspiration was performed under general anesthesia. During marrow aspiration, the needle was continuously moved around at 45°<sup>18</sup>. A centrifuge (Cence®; 8 minutes, 3200 rpm, 1600 rcf pressure, free rotor, cooled) was used to increase the stem cell content of the aspirate (Figure 1).

A combination of preoperative magnetic resonance imaging (MRI) and fluoroscopy were used to locate the necrotic segment of the femoral head. The lesion was monitored using fluoroscopy, and was reached using a 2-mm Kirschner wire (K-wire). A 2-cm lateral incision was made over the trochanter major, corresponding to the K-wire entrance with fluoroscopic guidance. An 8.5-mm tubular reamer mosaicplasty cannula (Mosaicplasty Autogenous Osteochondral Grafting System; Smith + Nephew, London, UK) was introduced with a hammer from the greater trochanter into the lesion under K-wire guidance. For the removal of the healthy osseous autograft lateral to the lesion, the system was advanced until the femoral head lesion was reached by hammering at first, and then turning it clockwise and counter-clockwise (Figure 2). The cannula was withdrawn, and the cortical and cancellous bone was removed as a block (Figure 3). The hole made by the K-wire was seen in the center of the vertical shaft of the autograft plug. This hole maintained the decompression of the pressure inside the femoral head after bone plug sliding. The removed autograft plug was kept in BMAC for 5 minutes (Figure 4).

The lesion and its surroundings were decompressed using a 6.5-mm drill through the previously created

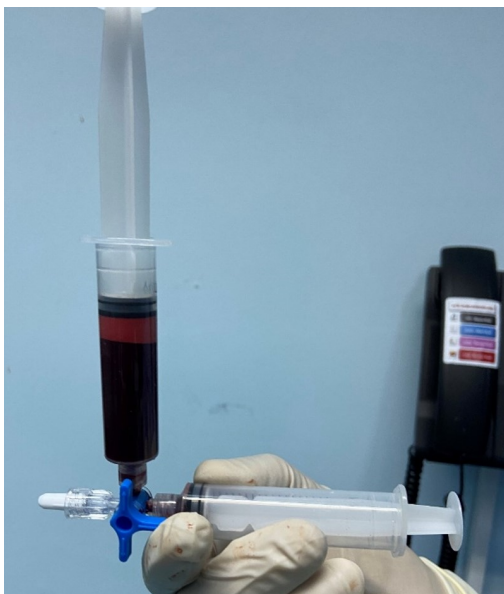

Figure 1. — Bone marrow aspirate after centrifugation.

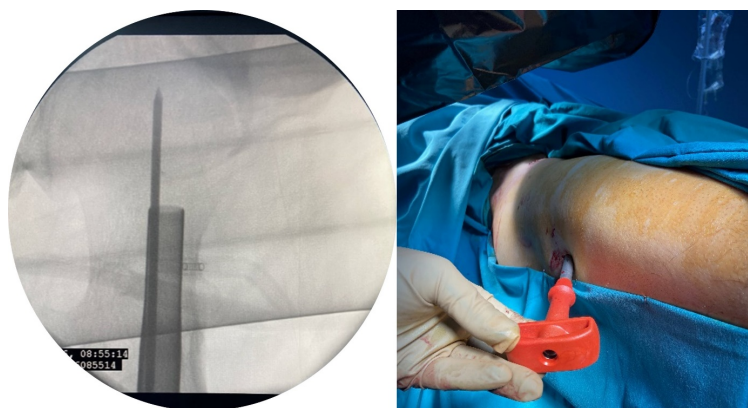


Figure 2. — K-wire and mosaicplasty cannula application under fluoroscopy guidance.

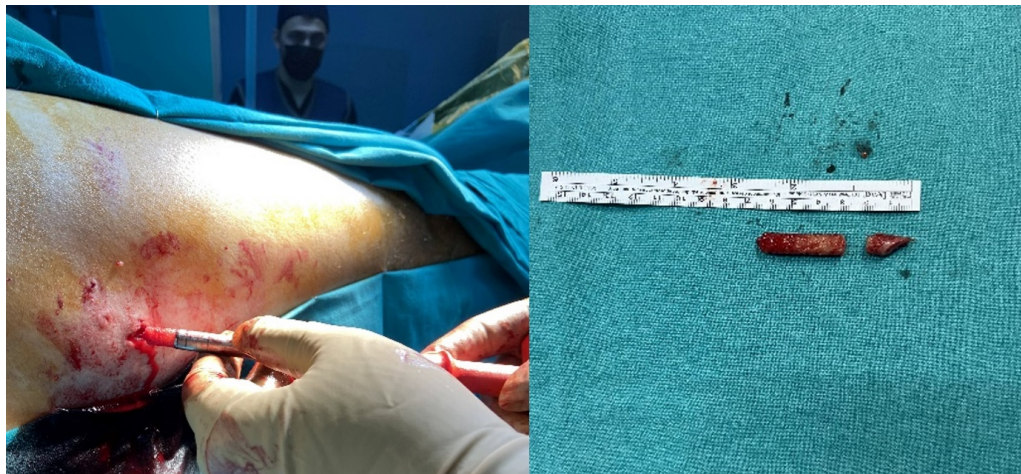


Figure 3. — Removal of the healthy corticospongious autograft lateral to the necrotic region.

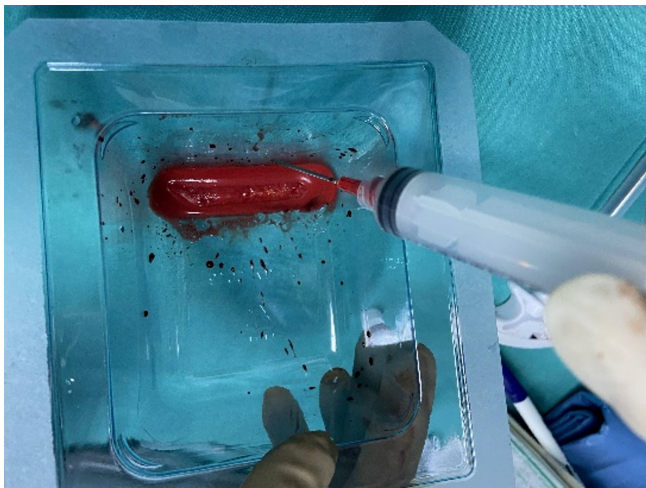


Figure 4. — a) The removed block was kept in BMAC for 5 minutes. b) The hole made by the K-wire is seen in the center of the vertical shaft of the autograft.

hole. Revitalization was attempted by performing curettage with a curved curette (Figure 5). Approximately 10 cc of BMAC was placed into the decompressed and curetted area using a trocar (Figure 5).

The corticospongious bone plug was removed from the extract, and put back into its place using a mosaicplasty cannula (Figure 5). Afterwards, 5 cc of BMAC was also injected into the hip joint, and the operation was completed by anatomically closing the layers.

Full weight-bearing was allowed on the first post-operative day, as tolerated by the patient. Vigorous mobilization and range-of-motion exercises were initiated immediately.

Patients were identified from the author (MCU) surgical databases. Between October 2019 and June 2021, 32 consecutive surgically-treated early-stage ONFH patients were screened for this study. The medical records of these patients were reviewed retrospectively. Only 18 patients treated with autologous bone plug-sliding and BMAC injection were included in the study. Plain radiographs of the bilateral hips in the anteroposterior and frog-leg lateral positions, as well as MRIs, were performed for all patients. The diagnosis of ONFH was based on clinical history and radiographic lesions in the femoral head.

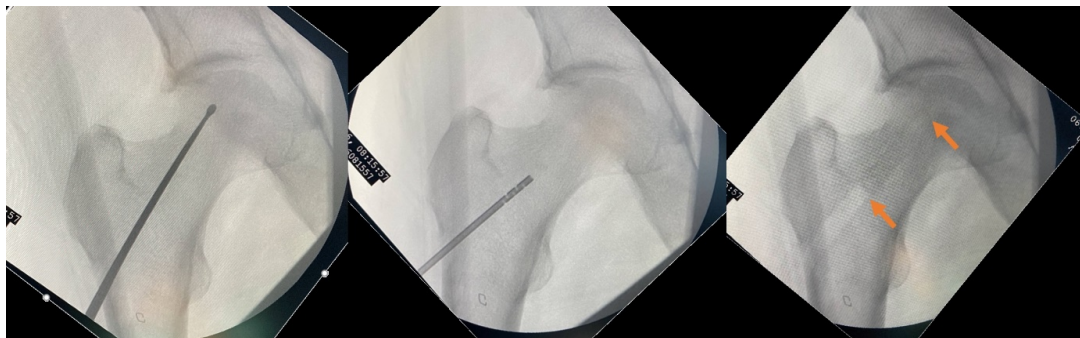


Figure 5. — Curettage of the necrotic region with a curved curette (left). Centrifuged bone marrow extract was applied to the decompressed and curetted area using a trocar (middle). The corticospongious bone block was put back into its place with the help of a mosaicplasty cannula. The arrows show its two ends (right).

The inclusion criteria were: 18-65 years age; notable hip pain; Ficat-Arlet stage 2 ONFH; and a history of steroid treatment, stopped at least 6 months ago. The exclusion criteria were: secondary osteoarthritic changes, such as osteophyte formation, narrowed joint gap, and osteosclerosis; history of proximal femur fracture, tumor, or any other concomitant lower extremity disease; history of any surgical treatment, in terms of core decompression, bone grafting, or osteotomy; history of any conservative treatment, such as extracorporeal shock wave therapy, hyperbaric oxygen, or alendronate; inflammatory arthritis, including rheumatoid arthritis, suppurative arthritis, and gouty arthritis; and pregnancy. All patients were clinically assessed preoperatively and at the last follow-up using Harris hip score (HHS) and Visual analogue scale (VAS). The radiological progression of the avascular necrosis stage was assessed by comparing pre- and post-treatment radiographs. All radiographs and MRI images were reviewed and staged by a musculoskeletal radiologist. Clinical and radiological deterioration was identified on the basis of worsening clinical scores, femoral head collapse, joint space narrowing, or the need for joint replacement.

The descriptive values were presented as means, standard deviation, and range. Statistical analysis was performed using SPSS Statistics version 20 (IMB Corp., Armonk, NY, USA). Dependent t-test was used to compare pre- and post-operative scores.

## RESULTS

Eighteen patients (29 hips) were found eligible for final inclusion, of which, 11 were operated bilaterally. There were 11 males and 7 females. Twenty-five hips had stage-2B ONFH, while the remaining were stage 2A. The average age was 39.8 years ( $\pm 11.7$ , range: 24-65 years). The average follow-up was 13.5 months ( $\pm 3.4$ , range: 8-19 months). The average HHS increased from 61.90 to 87.45, while average VAS pain score decreased from 7.14 to 3.27, which were both statistically

**Table I.** — Statistical comparison of pre- and post-operative Harris hip & VAS pain score

	<i>Average</i>	<i>SD (range)</i>	<i>P value</i>
<b>Harris Hip Score</b>			
<i>Preoperative</i>	61.90	10.59 (43-79)	< 0.001*
<i>Postoperative</i>	87.45	10.40 (72-96)	
<b>VAS pain</b>			
<i>Preoperative</i>	7.14	1.48 (5-9)	< 0.001*
<i>Postoperative</i>	3.27	1.52 (0-5)	
VAS, visual analogue scale; SD, standard deviation.			

significant ( $p < 0.001$ ; Table I). No complications were encountered. All patients showed improvements in clinical scores, and none of the patients had collapsed femoral heads or required hip arthroplasty.

## DISCUSSION

We analyzed the surgical outcomes of core decompression of pre-collapse ONFH with autologous bone plug-sliding and BMAC application in 29 hips (18 patients) with a history of systemic steroid treatment.

The etiology of ONFH is not fully understood, but steroid use, sickle cell anemia, fat embolism, alcohol use, and trauma are among the most common causes. Up to 20,000 patients are diagnosed with ONFH every year in the USA alone, and this rate is expected to increase due to extensive steroid usage during the COVID 19 pandemic<sup>14</sup>. Steroid-induced ONFH increases osteocyte apoptosis, and decreases osteoblastogenesis and bone repair response. Progenitor cell-derived osteoblasts play a main role in the repair of necrotic areas and bone remodeling. The presence of progenitor cells, and the resultant osteoblasts, in the necrotic areas in the early stages before cartilage collapse directly affect the prognosis<sup>21,22</sup>. This suggests that osteoprogenitor cells are needed for treatment of steroid-induced avascular necrosis. As osteoprogenitor capacity decreases with age, the use of BMAC, especially in older patients, might be important<sup>23</sup>. BMAC provides not only mesenchymal stem cells but also vascular endothelial growth factor (VEGF), bone morphogenetic protein (BMP)-2, BMP-6, other growth factors, hemopoietic cells, and platelets to promote angiogenesis. In recent years, there have been promising studies on the use of autologous stem cells in ONFH<sup>6,8</sup>.

The conventional core decompression technique is aimed at increasing the blood supply in the necrotic area by reducing the pressure. Although this method is effective, especially in the early stages where the cartilage surface has not collapsed, the rate of progression to osteoarthritis remains too high to be overlooked<sup>17</sup>. This has directed researchers to investigate better treatment modalities. A meta-analysis concluded that additional procedures, like BMAC, vascularized fibular grafting, electrical stimulation, etc., can provide better clinical results compared to core decompression alone<sup>16</sup>.

Gangji et al. demonstrated that osteoprogenitor cell changes in steroid-induced ONFH patients were isolated to the proximal femur, and no pathologies were detected in the iliac crest medulla<sup>6</sup>. This makes the iliac crest an excellent option for obtaining BMAC. A standard 4-6 mL bone marrow aspiration concentrate

can be produced by centrifugation of 60 mL of bone marrow aspirate, and contains approximately 40,000 mesenchymal stem cells<sup>4</sup>. Many authors have recommended 60-120 mL of bone marrow aspiration, and injection of 6-15 mL BMAC into the lesion area after centrifugation<sup>3,11</sup>.

Gangji et al. compared the efficacy of core decompression with and without BMAC in 19 ONFH patients<sup>7</sup>. They reported better clinical outcomes when BMAC was added to core decompression. Kang et al. compared core decompression with and without BMAC application, and found that BMAC lowers the rate of conversion to total hip arthroplasty<sup>11</sup>. Our results also revealed that autologous bone plug-sliding with core decompression and BMAC application provided acceptable clinical outcomes, and none of the patients progressed to advanced stages or required total hip replacement.

Although core decompression with BMAC application seems to be a valuable option, several problems exist. Since the hole through which the femoral head is decompressed stays open, the applied BMAC cannot be stabilized in the necrotic area and may leak through this hole. In addition, it does not provide structural support to the decompressed and debrided femoral head. To overcome the lack of structural support, allografts and non-vascularized or vascularized autografts may be used<sup>2,24</sup>. A randomized controlled study by Cao et al. compared core decompression with vascularized fibular autografting, and found that autografts improved the vascularity and reduced the progression of osteonecrosis<sup>2</sup>. However, donor site morbidity is an important limitation for this technique. To avoid donor site morbidity, allograft use has been reported. A systematic review by Yue et al. reported that fibula allograft propping can provide successful outcomes in the management of ONFH<sup>24</sup>. However, the number of articles included in the study was small, and most of the studies were retrospective with a low level of evidence. In addition, the risk of disease transmission is a major concern related to allograft usage, and it is not easy to find sufficient allografts to meet the clinical demand<sup>13</sup>.

The technique described in the present study is simple and effective, and addresses the problems mentioned earlier. First of all, the debrided necrotic area in the femoral head does not have an effective progenitor cell count. The healthy cancellous bone block, obtained from the lateral trochanteric region and transferred to the necrotic region, provides osteoconductive and osteoinductive effects, and increases the effectiveness of BMAC. Additionally, it provides structural support to the femoral head, holds the

BMAC in the area of application, reservoirs BMAC fluid behind it, and prevents its leakage. There is also continuous decompression of the necrotic region at the femoral head owing to the hole in the middle of bone plug made by the K-wire. In contrast to other techniques that provide structural support (vascularized or non-vascularized autografts), our technique has no donor site morbidity or risk for disease transmission. The additional intra-articular BMAC application in this technique further facilitates regeneration by providing a better microenvironment for cartilage regeneration<sup>10</sup>. The corticospongiuous bone plug is placed in the defect in a press-fit manner, leading to better osteointegration than other autografts, which have a size mismatch with the defect. Corticospongiuous bone plug also provides a shell for the mesenchymal stem cells from BMAC.

The main limitations of this study were the lack of a control group and the retrospective study design. We did not analyze the patients with postoperative MRIs to reduce the costs.

Autologous bone plug-sliding with core decompression and a BMAC application technique filled the defects, facilitated healing at the necrotic site in patients with altered micro-circulation due to corticosteroid use<sup>15</sup>, and protected the joint cartilage during early weight-bearing.

## CONCLUSION

Autologous bone plug-sliding with core decompression and a BMAC application technique is effective in early-stage corticosteroid-induced ONFH patients, with excellent symptomatic outcomes. Furthermore, immobilization is not required, which permits safe and early return to function and weight-bearing.

## REFERENCES

1. Auyeung T, Lee J, Lai W, et al. The use of corticosteroid as treatment in SARS was associated with adverse outcomes: a retrospective cohort study. *J Infect* 2005 ; 51 : 98-102.
2. Cao L, Guo C, Chen J, et al. Free Vascularized Fibular Grafting Improves Vascularity Compared With Core Decompression in Femoral Head Osteonecrosis: A Randomized Clinical Trial. *Clin Orthop Relat Res* 2017 ; 475 : 2230-2240.
3. Chahla J, Dean CS, Moatshe G, et al. Concentrated Bone Marrow Aspirate for the Treatment of Chondral Injuries and Osteoarthritis of the Knee: A Systematic Review of Outcomes. *Orthop J Sport Med* 2016 ; 4 : 2325967115625481.
4. Chahla J, Mannava S, Cinque ME, et al. Bone Marrow Aspirate Concentrate Harvesting and Processing Technique. *Arthrosc Tech* 2017 ; 6 : e441-e445.
5. Cohen-Rosenblum A, Cui Q. Osteonecrosis of the Femoral Head. *Orthop Clin North Am* 2019 ; 50 : 139-149.
6. Gangji V, Hauzeur J-P. Treatment of osteonecrosis of the femoral head with implantation of autologous bone-marrow

- cells. Surgical technique. *J Bone Joint Surg Am* 2005 ; 87 Suppl 1 : 106-12.
7. Gangji V, De Maertelaer V, Hauzeur J-P. Autologous bone marrow cell implantation in the treatment of non-traumatic osteonecrosis of the femoral head: Five year follow-up of a prospective controlled study. *Bone* 2011 ; 49 : 1005-1009.
  8. Gao Y-S, Zhang C-Q. Cytotherapy of osteonecrosis of the femoral head: a mini review. *Int Orthop* 2010 ; 34 : 779-82.
  9. Hernigou P, Beaujean F. Treatment of Osteonecrosis With Autologous Bone Marrow Grafting. *Clin Orthop Relat Res* 2002 ; 405 : 14-23.
  10. Jin Q-H, Chung Y-W, Na S-M, et al. Bone marrow aspirate concentration provided better results in cartilage regeneration to microfracture in knee of osteoarthritic patients. *Knee Surgery, Sport Traumatol Arthrosc* 2021 ; 29 : 1090-1097.
  11. Kang JS, Suh YJ, Moon KH, et al. Clinical efficiency of bone marrow mesenchymal stem cell implantation for osteonecrosis of the femoral head: a matched pair control study with simple core decompression. *Stem Cell Res Ther* 2018 ; 9 : 274.
  12. Koo KH, Kim R, Ko GH, et al. Preventing collapse in early osteonecrosis of the femoral head. A randomised clinical trial of core decompression. *J Bone Joint Surg Br* 1995 ; 77 : 870-4.
  13. Lomas R, Chandrasekar A, Board TN. Bone Allograft in the UK: Perceptions and Realities. *HIP Int* 2013 ; 23 : 427-433.
  14. Moya-Angeler J, Gianakos AL, Villa JC, et al. Current concepts on osteonecrosis of the femoral head. *World J Orthop* 2015 ; 6 : 590-601.
  15. Perretti M, Ahluwalia A. The microcirculation and inflammation: site of action for glucocorticoids. *Microcirculation* 2000 ; 7 : 147-61.
  16. Sadile F, Bernasconi A, Russo S, et al. Core decompression versus other joint preserving treatments for osteonecrosis of the femoral head: a meta-analysis. *Br Med Bull* 2016 ; 118 : 33-49.
  17. Sen R. Management of avascular necrosis of femoral head at pre-collapse stage. *Indian J Orthop* 2009 ; 43 : 6.
  18. Talathi NS, Kamath AF. Autologous stem cell implantation with core decompression for avascular necrosis of the femoral head. *J Clin Orthop Trauma* n.d. ; 9 : 349-352.
  19. Tomazini BM, Maia IS, Cavalcanti AB, et al. Effect of Dexamethasone on Days Alive and Ventilator-Free in Patients With Moderate or Severe Acute Respiratory Distress Syndrome and COVID-19. *JAMA* 2020 ; 324 : 1307.
  20. Wang X-S, Zhuang Q-Y, Weng X-S, et al. Etiological and clinical analysis of osteonecrosis of the femoral head in Chinese patients. *Chin Med J (Engl)* 2013 ; 126 : 290-5.
  21. Weinstein RS, Jilka RL, Parfitt AM, et al. Inhibition of osteoblastogenesis and promotion of apoptosis of osteoblasts and osteocytes by glucocorticoids. Potential mechanisms of their deleterious effects on bone. *J Clin Invest* 1998 ; 102 : 274-82.
  22. Weinstein RS, Nicholas RW, Manolagas SC. Apoptosis of osteocytes in glucocorticoid-induced osteonecrosis of the hip. *J Clin Endocrinol Metab* 2000 ; 85 : 2907-12.
  23. Yudoh K, Matsuno H, Osada R, et al. Decreased cellular activity and replicative capacity of osteoblastic cells isolated from the periarticular bone of rheumatoid arthritis patients compared with osteoarthritis patients. *Arthritis Rheum* 2000 ; 43 : 2178-88.
  24. Yue J, Gao H, Guo X, et al. Fibula allograft propping as an effective treatment for early-stage osteonecrosis of the femoral head: a systematic review. *J Orthop Surg Res* 2020 ; 15 : 206.
  25. Zhang S, Wang C, Shi L, et al. Beware of Steroid-Induced Avascular Necrosis of the Femoral Head in the Treatment of COVID-19—Experience and Lessons from the SARS Epidemic. *Drug Des Devel Ther* 2021 ; Volume 15 : 983-995.