

Minimally invasive corrective derotational osteotomy for proximal phalanx malrotation

P. CAEKEBEKE, L. VAN MELKEBEKE, J. DUERINCKX

Ziekenhuis Oost-Limburg, Departement of Orthopaedic Surgery, Genk, Belgium.

Correspondence at: Pieter Caekebeke, ZOL Genk, Synaps Park 1, Genk, Belgium, Phone: +32-89-326118, Email: Pieter.caekebeke@zol.be

Fractures of the phalanges may result in a challenging complication known as malrotation, which can adversely affect the functionality of the fingers during flexion, leading to scissoring. The standard surgical approach for correcting this condition involves open corrective osteotomy and derotation, often at the level of the metacarpal, which includes the use of different techniques for osteotomy and fixation. However, postoperative complications such as finger stiffness and hardware irritation are common. To overcome these limitations, we present a novel and minimally invasive corrective osteotomy technique for malunited proximal phalanx fractures with rotational malalignment, which offers several advantages, such as accelerated rehabilitation and no prominent hardware.

Keywords: Phalanx, corrective, osteotomy, intramedullary, malunion, malrotation.

INTRODUCTION

Phalangeal fractures of the fingers are common injuries. They typically result from a direct blow, rotary force, or hyperextension trauma. Less than 10 degrees of angulation and up to 2 mm of shortening can generally be tolerated. In contrast, even minimal rotational deformity may cause functional problems¹. Malrotation of a phalangeal fracture can lead to scissoring or overlapping of the fingers, causing cosmetic deformity, functional deficit and decreased grip strength. Malrotation of as little as 5 degrees of the proximal phalanx can cause 1.5 cm of digital overlap². This is difficult to detect on radiographic examination and may not become apparent until the digits regain a certain level of active joint mobility. Several surgical techniques have been described to correct malrotation of the proximal phalanx after bony healing has occurred. A wide-open exposure is typically required to perform the osteotomy and subsequent bone fixation, but this may result in postoperative stiffness due to scar formation and tendon adhesions³. For this reason, correction of phalangeal malrotation at level of the metacarpal has been suggested as an alternative⁴. In this article, we describe our experience with a new minimal invasive technique to correct rotational malunions of the proximal phalanx at the level of the initial injury, while avoiding extensive iatrogenic soft tissue scarring.

MATERIALS AND METHODS

Indications/contraindications

This technique is indicated for patients with symptomatic rotational malunion of the proximal phalanx. Associated longitudinal malalignment can be corrected simultaneously. Contraindications for this technique include fibrous nonunion, large bony defects, local infection, difficulty in flexing the proximal interphalangeal joint (PIP) sufficiently to obtain the ideal starting point for retrograde wire placement, overly large or small medullary canals, and noncompliant patients. Preoperative radiographs of the hand are sufficient to plan the operation, allowing for measurement of the length and inner diameter of the involved metacarpal and evaluation of the presence of angular deformity. The severity of malrotation cannot be accurately measured on radiographs and must be evaluated clinically.

Surgical anatomy

The lateral approach is preferred to access the proximal phalanx due to its minimal disturbance to the tendons. During surgery, preservation of digital nerves and arteries is of utmost importance. The dimensions of the proximal phalanx should be evaluated and taken into consideration during the procedure. Length ranges between 29-52mm and the narrowest diameter

is located at the isthmus⁵. For this technique, we use a cannulated compression screw (CCS, Medartis, Basel, Switzerland) but other types of headless compression screws can be used. We use a 3.0mm diameter screw for the proximal phalanx and a 2.0mm diameter screw for the middle phalanx. The length of the screw highly varies depending on finger that is treated. The aim is to achieve the maximum length to improve stability with the screw fully seated inside the phalanx.

Surgical approach to phalangeal malunion

Setup

The patient is placed in supine position with the involved upper limb on a radiolucent arm table. The surgery can be carried out under locoregional, general anesthesia or waland with a tourniquet and antibiotic prophylaxis.

Preliminary placement of the guidewire

A small transverse 3-mm incision is made at level of the distal articular surface of the phalangeal head with the PIP joint in maximal flexion. The central slip of the extensor tendon is split longitudinally. A guide wire is placed centrally on the articular surface and drilled retrograde into the medullary canal until just proximal of the intended osteotomy site (Figure 1). Central placement is verified with fluoroscopy on posteroanterior and lateral views.

Derotation and screw placement

The malunion site is localized with fluoroscopy. At this level, a 1 cm midlateral or dorsal longitudinal skin

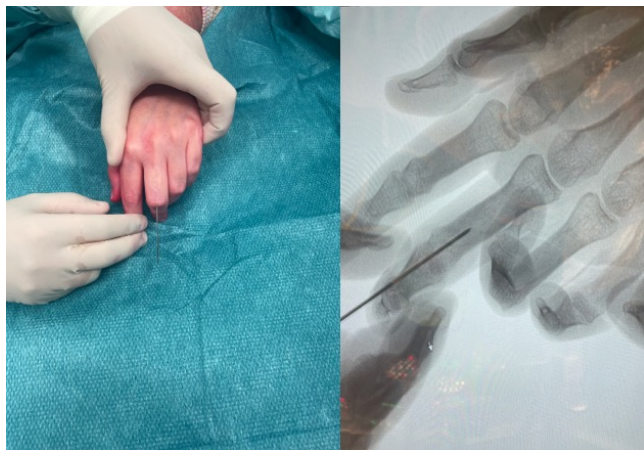

Figure 1. — Guide wire placement into proximal phalanx of the third digit.

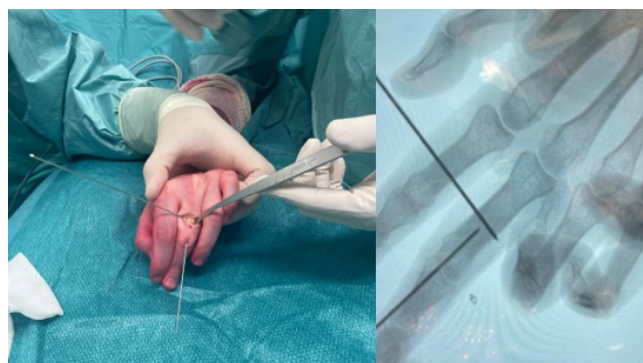


Figure 2. — Two sharp Homan retractors are placed around the bone at level of the planned osteotomy. The osteotomy site is predrilled with K-wires.

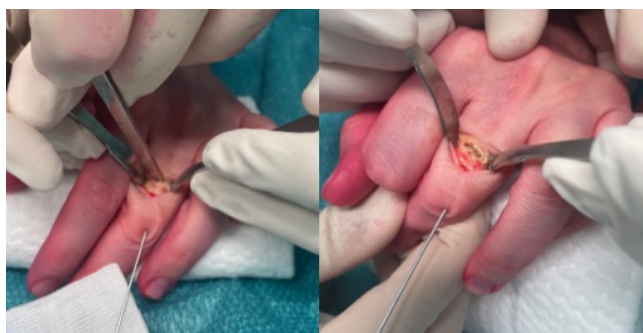


Figure 3. — The osteotomy is completed with an osteotome.

incision is made. We advise a midlateral incision as it minimizes tendon disturbance. We use a dorsal incision in case of previous surgery where a dorsal approach was used. The extensor and flexor tendons surrounding the proximal phalanx are retracted by placing sharp Homan retractors around the dorsal and palmar side of the malunion. A 1,0 mm Kirschner wire is passed multiple times through the bone at level of the malunion, avoiding laceration of tendons and neurovascular bundles (Figure 2). A 1 cm wide osteotome is used to complete the osteotomy perpendicular to the longitudinal axis of the phalanx (Figure 3). The intramedullary guide wire is advanced further retrograde into the phalanx, crossing the site of the osteotomy (Figure 4). Next, the malrotation is corrected by holding the fingers correctly aligned with the MCP and PIP joints in 90° of flexion. A cannulated drill bit is used to open the articular surface. Screw length is measured. This is easily done by holding a screw over the finger under fluoroscopy and determine the adequate length. It is important to seat the screw completely in the phalanx as not to disturb the proximal and distal joint during motion. A headless compression screw is inserted until it is deeper than the articular surface of the phalangeal head and centered

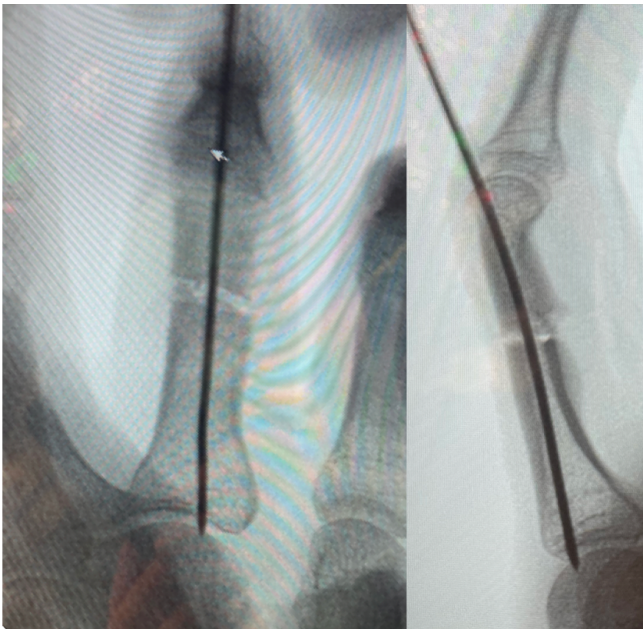


Figure 4. — Retrograde placement of guide wire in the intramedullary canal.

over the osteotomy site. Screw position is checked with fluoroscopy (Figure 5).

Closure

The extensor tendon split is closed with simple resorbable stitches 4/0. Both skin incisions are closed with a few interrupted stitches nylon 5/0.

Rehabilitation

The intramedullary screw provides adequate stability to allow immediate active range of motion exercises of the fingers⁶. Buddy taping of the operated finger to an adjacent one is encouraged to control finger rotation. Skin stitches are removed at 10 to 14 days postoperatively. At 6 weeks after surgery, clinical and radiologic follow-up is organized, and loading and strengthening exercises are allowed upon confirmation of bony healing (Figure 6).

Expected Outcomes

This technique offers a simplified approach to a complex procedure while reducing the risk of tendon adhesions and hardware-related irritation. Our clinical experience includes four patients, consisting of three males and one female. Average patient age was 32 years. Two patients underwent treatment for malrotation of the proximal phalanx of the third finger, one for the fourth and one for the second finger. One

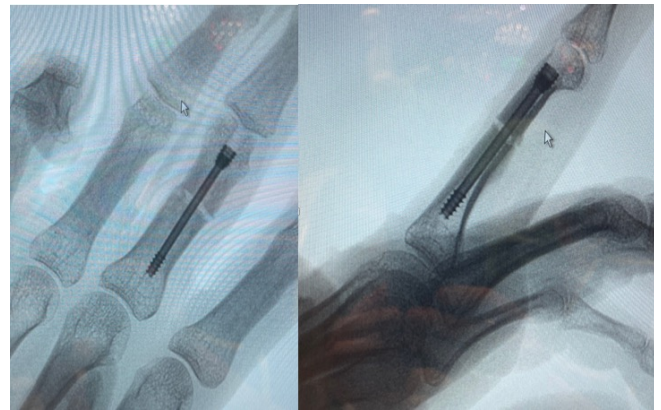

Figure 5. — Postoperative radiographs. Intramedullary screw in the proximal phalanx.

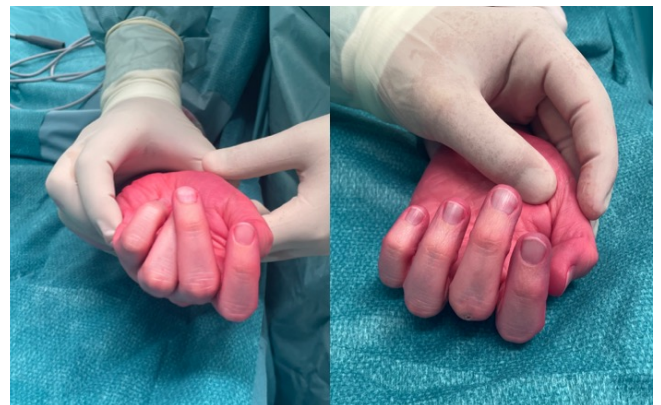

Figure 6. — Clinical pictures. Preoperative (left) with visible malrotation of the fifth finger. Postoperative (right) shows adequate correction.

patient was initially treated with plate and screw osteosynthesis, the remaining fractures were initially managed conservatively. All corrective surgeries were uneventful. Postoperative radiological evaluation demonstrated adequate bone healing of all osteotomies after an average period of 6,9 weeks. Clinical evaluation revealed satisfactory correction of rotational deformity without the need for secondary tenolysis, capsulotomy, or screw removal. No intraoperative or postoperative complications were observed.

Possible complications

While intramedullary headless compression screw fixation has many advantages for the treatment of rotational malunion of the finger, certain difficulties and complications can be associated with this technique. During surgery, filling of the intramedullary canal with sclerotic bone at the level of the healed fracture can block proper advancement of the guide wire. This can be

countered by exposing both ends of the intramedullary canal at level of the osteotomy and to open them with an awl. Postoperatively, progressive loss of rotational reduction is another possible complication. Due to the irregular edges of the osteotomy created by drill holes, the transverse osteotomy combined with a round intramedullary device may not provide optimal rotational stability along the long axis of the bone. However, the compression provided by the screw appears to be sufficient to maintain the rotational correction until bone healing has occurred. To prevent the risk of pseudoarthrosis, we advise against using an oscillating saw to perform the osteotomy, as it can cause thermal necrosis of the bone, and we prefer to apply protective buddy taping in the postoperative period until bone healing has occurred.

DISCUSSION

Posttraumatic rotational finger deformity is poorly tolerated². When caused by malunion of a phalangeal fracture, corrective osteotomy presents several challenges for the surgeon. First, the exact location of a purely rotational malunion can be difficult to pinpoint on radiographs. If so, the osteotomy is best planned at level of the diaphysis to ensure adequate purchase of the intramedullary screw. Second, the technique proposed in this article allows true minimal incision surgery to minimize the chance of postoperative scarring and loss of range of motion. This is a major advantage of intramedullary screw fixation over plate and screw osteosynthesis³. Headless intramedullary screws have been clinically and biomechanically proven to be sufficiently stable to allow early active range of motion, even after rotational osteotomies^{6,7}. Recently, the first results of corrective osteotomies of phalanx and metacarpal malunions have been published showing the fixation technique to be sufficient to permit immediate range of motion⁸. In this series, all phalanx cases were for malrotation. Our previous biomechanical analysis showed that screw fixation is also possible for angular malunions⁶ but further clinical research is needed to validate screw fixation for this indication.

CONCLUSION

The clinical cases discussed in this article illustrate the effectiveness of using intramedullary headless compression screws to stabilize derotation corrective osteotomy in patients experiencing problematic finger scissoring due to malunion of the proximal phalanges. This technique offers theoretical advantages over plate fixation by lowering the incidence of revision surgery caused by soft tissue irritation and adhesion. Additionally, it provides sufficient stability for early, gentle active range of motion.

Acknowledgement: This research received received financial support of the Orthopaedic Research Foundation Genk.

Declaration of conflicting interests: All named authors hereby declare that they have no conflicts of interest to disclose.

REFERENCES

1. Jones NF, Jupiter JB, Lalonde DH. Common fractures and dislocations of the hand. *Plast Reconstr Surg.* 2012;130(5):722e-36e.
2. Freeland AE, Lindley SG. Malunions of the finger metacarpals and phalanges. *Hand clinics.* 2006;22(3):341-55.
3. von Kieseritzky J, Nordstrom J, Arner M. Reoperations and postoperative complications after osteosynthesis of phalangeal fractures: a retrospective cohort study. *J Plast Surg Hand Surg.* 2017;51(6):458-62.
4. Bindra RR, Burke FD. Metacarpal osteotomy for correction of acquired phalangeal rotational deformity. *The Journal of hand surgery.* 2009;34(10):1895-9.
5. Ash HE, Unsworth A. Proximal interphalangeal joint dimensions for the design of a surface replacement prosthesis. *Proc Inst Mech Eng H.* 1996;210(2):95-108.
6. Deschuyffeleer S, Duerinckx J, Caekebeke P. In vitro Biomechanical Analysis of Proximal Phalangeal Osteotomy Fixation. *J Wrist Surg.* 2021;10(2):154-7.
7. Duerinckx J, Caekebeke P. Minimally Invasive Corrective Osteotomy for Metacarpal Malrotation. *Techniques in hand & upper extremity surgery.* 2021;26(1):47-50.
8. Del Pinal F, Ananos D, Ruas JS, Mazarrasa R, Studer AT. Minimally Invasive Procedure for Correcting Extra-Articular Malunions of Metacarpals and Phalanges. *The Journal of hand surgery.* 2023;48(5):511 e1- e10.