

ULNAR DIMELIA

L. DE SMET

A case of ulnar dimelia with good preservation of upper limb function is described. In this particular case an association with liver cirrhosis, idiopathic scoliosis and dislocatable shoulder was observed.

Keywords : mirror hand ; polydactyly, scoliosis ; ulnar dimelia.

Mots-clés : main en miroir, polydactylie, scoliose ; dimélie ulnaire.

INTRODUCTION

Ulnar dimelia, or mirror hand, is probably the most exceptional congenital anomaly of the upper limb. The appearance is so striking that the diagnosis is obvious. The abnormality consists of a duplication of the ulna and the ulnar part of the hand and absence of radial structures. The hand is symmetrical with too many fingers, usually seven, but no thumb.

Only a few cases have been described (2, 6, 9). We report an additional case, associated with idiopathic scoliosis and liver cirrhosis.

CASE REPORT

A 19-year-old girl was seen with a congenital malformation of the right arm. She was born with a 6-fingered hand, of which one was removed and one was transposed and shortened (pollicisation). At the age of 14, the proximal carpal bones were resected to improve her wrist mobility.

The father of the girl was unknown ; she was raised by her grandparents. According to them the mother was molested and extremely malnourished during pregnancy.

She had a 10-cm shortening of the involved arm ; the shoulder could be voluntarily dislocated and the clavicle was hypotrophic. The elbow was stiff in extension and rotation was impossible. The wrist could be moved from 80° of flexion to full (0°) extension. Mobility of the fingers and thumb was practically normal (fig. 1).

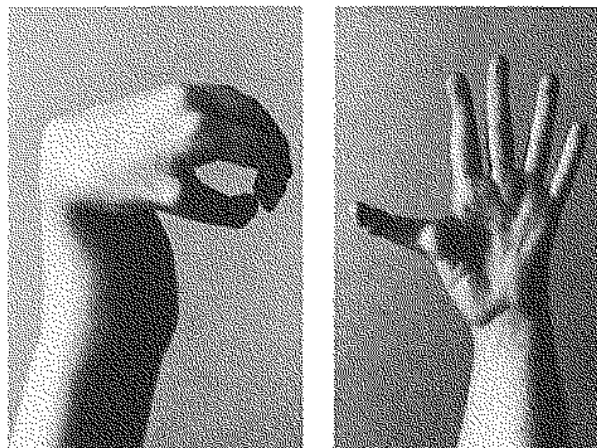


Fig. 1. — Near normal flexion (a) and extension (b) of all fingers.

On the radiographs the particular configuration of the elbow was striking (fig. 2) : the radius was absent and the ulna was duplicated ; each ulna was angulated 90° to the other. The shoulder and wrist were also noteworthy (fig. 3, 4).

She also presented idiopathic scoliosis without morphological abnormalities of the vertebrae. The lower limbs were normal. According to her history and her record, she also suffered from liver cirrhosis and esophageal varices, which had been sclerosed. A liver biopsy in 1993 demonstrated

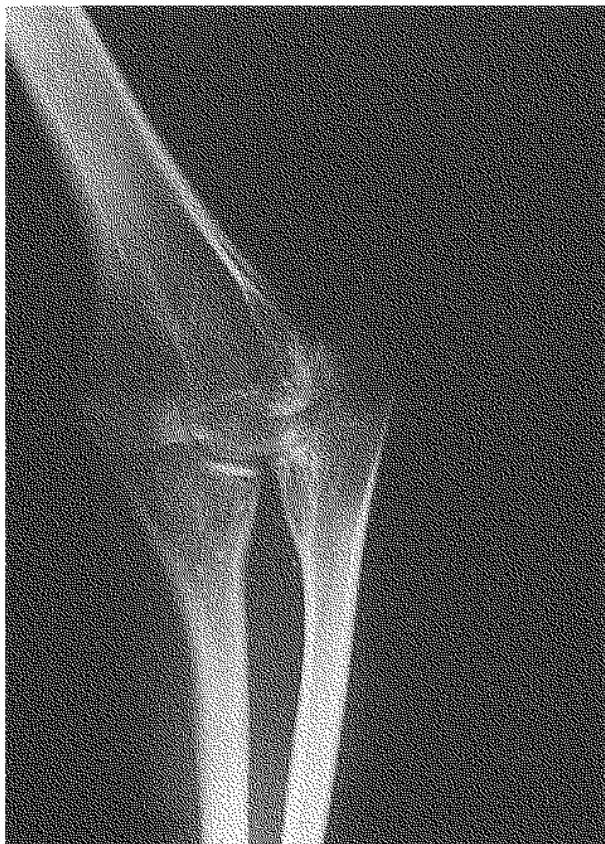

Fig. 2. — Radiograph of the elbow showing duplication of the ulna and absence of the radius.

micronodular cirrhosis with copper deposits in the hepatocytes and mild focal microvacuolar steatosis. At the present visit her liver tests were within normal limits with a copper of $149\mu\text{g}/100\text{ml}$; ceruloplasmin was normal. No esophageal bleeding had occurred since the treatment started in 1993.

DISCUSSION

Duplication of the ulna with absence of the radius is known as ulnar dimelia. According to Wood and Green (9) the following features are present: limited elbow flexion, absent or limited pronation, flexion contracture and radial deviation of the wrist, weak finger extension, absent thumb and thumb web, polydactyly, syndactyly and palmar cleft. Only a limited number of cases have been well described and published (2, 3, 4, 5, 6, 9).

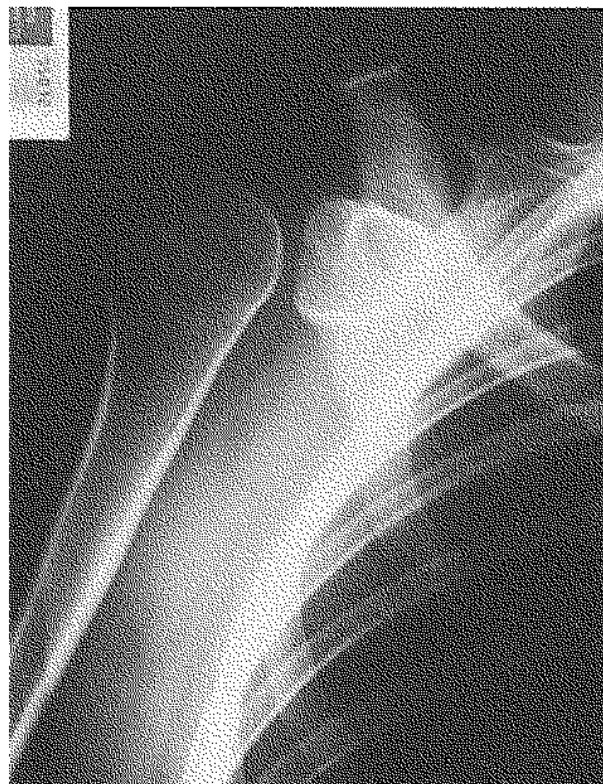

Fig. 3. — Radiograph of the shoulder with deformity of the humeral head and glenohumeral dislocation.

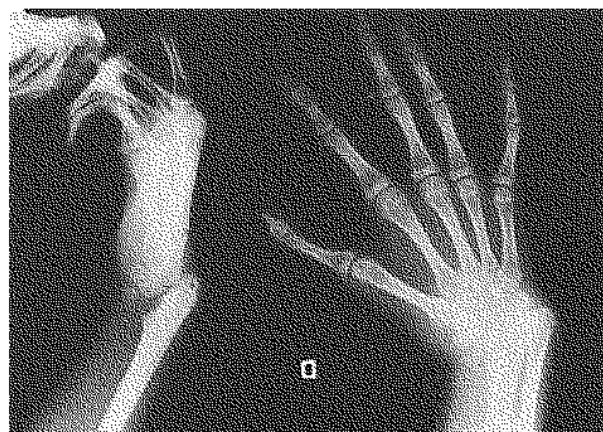


Fig. 4. — Radiograph of the hand.

The present case is peculiar in that despite the extreme malformations, the general function was good with good hand function in particular. The association with ipsilateral dislocatable shoulder, scoliosis and cirrhosis has not been described.

Ulnar dimelia can be experimentally provoked by transplantation of a zone of polarizing activity of one limb bud to the cranial side of another one (1). The cause remains unknown, but the physical maltreatment during pregnancy may be blamed in this case. An autosomal dominant syndrome known as Laurin-Sandrow with bilateral mirror hand and feet, absent radii and tibiae and nasal defects has been described (6, 8). Chromosomal abnormalities have recently been observed in this syndrome (OMIM 135750). The gene map locus is 14q13 (7).

A treatment protocol has been suggested by Wood and Green, based on their own experience and a review of the literature (9). The elbow can be made mobile by resection of the proximal end of one of the ulnae. The wrist should be stabilized by soft tissue procedures, proximal row resection, osteotomy or arthrodesis. The hand can be reconstructed by removal of the excessive finger(s) and transposition of one of the fingers into the thumb position (pollicization). This patient was offered a reconstructive procedure for the elbow but she refused.

REFERENCES

1. Alberts B., Bray D., Lewis J. Molecular Biology of the Cell, Garland, New York, 1983.
2. Barton N., BUCK-Gramcko D., Evans D. Soft tissue anatomy of mirror hand. J. Bone Joint Surg., 1986, 11-B, 307-319.
3. Davis R., Farmer A. Mirror hand anomaly. Plast. Reconstr. Surg., 1958, 21, 80-83.

4. Harrison R., Pearson M., Roaf R. Ulnar dimelia. J. Bone Joint Surg., 1960, 42-B, 549-555.
5. Hersh J., Dela Cruz T., Pietrnatoni M., Von Drasek-Ascher G., Turnquest M., Yacoub O., Joyce M. Mirror image duplication of the hands and feet. Am. J. Med. Genet., 1995, 59, 341-345.
6. Laurin C., Faveau J., Labelle P. Bilateral absence of the radius and tibia with bilateral reduplication of the ulna and fibula. J. Bone Joint Surg., 1964, 46-A, 137-142.
7. Online Mendelian inheritance in man. [Http://www3.ncbi.nlm.nih.gov/omim](http://www3.ncbi.nlm.nih.gov/omim) ; OMIM 135750.
8. Sandrow R., Sullivan P., Steel. Hereditary ulnar and fibular dimelia with peculiar facies : A case report. J. Bone Joint Surg., 1970, 52-A, 367-370.
9. Wood V., Green D. (ed). Operative Orthopaedics. Churchill Livingstone, New-York, 1988, pp. 485-491.

SAMENVATTING

L. DE SMET. Ulnaire dimelie.

Een geval van ulnaire dimelie met algemeen goede functie van het bovenste lidmaat wordt beschreven. Dit geval is geassocieerd met cirrhose, scoliose en een onstabiele schouder.

RÉSUMÉ

L. DE SMET. Dimélie ulnaire.

Un cas de dimélie ulnaire avec bonne fonction du membre supérieur est décrit. Dans ce cas particulier, une association avec une cirrhose hépatique, une scoliose idiopathique et une épaule instable était observée.