

BLEEDING FROM THE LATERAL CIRCUMFLEX ARTERY FOLLOWING TOTAL HIP REPLACEMENT, TREATED BY EMBOLIZATION

E. DE GROOF, D. VIOLON, P. HERMANS, J. BOGHEMANS

A patient with bleeding from the lateral circumflex artery following total hip replacement was successfully treated by embolization. The mechanism of injury and treatment modalities are discussed.

Keywords : hip replacement ; postoperative bleeding ; embolization ; arterial injuries ; surgical complication ; hematoma.

Mots-clés : arthroplastie totale ; hanche ; saignement post-opératoire ; embolisation ; traumatisme artériel ; complication chirurgicale ; hématome.

INTRODUCTION

Arterial injuries after total hip replacement (THR) are very rare (1, 4, 7, 8, 14, 15, 18). Nachbur in 1979 (10) estimated the rate of vascular lesions following THR to be 0.25%. This would indicate some 100 cases a year for an estimated 350,000 THR's a year. Bergqvist (3) even reported 3 vascular injuries during 250 THR's : an incidence of over 1%. However, the largest published series to date has been that of Ratliff (13) reporting 32 cases. This probably indicates that many cases go unreported and that the problem is being seriously underestimated (16).

With the increasing number of THR's being performed and especially of revision operations, such surgery is and will probably be increasingly performed by less experienced surgeons, thus tending to augment the incidence of vascular injuries (14).

We report a case of injury to the lateral circumflex artery because of its rarity ; we are aware of no more than 2 such cases (10). However, we think that this injury might be the cause of severe post-

operative hematomas, predisposing among other things to secondary deep infection.

CASE REPORT

A 62-year-old male suffering from severe, bilateral osteoarthritis of the hip was admitted to our department. A left THR was performed on November 3, 1988 using a threaded cup and a cemented straight stem using a lateral approach (11). The patient recovered uneventfully.

A right THR was performed on March 28, 1990 using the same type of prosthesis and incision. During surgery, no exceptional problems were encountered although the patient weighed over 100 kg. On April 4, a considerable volume of fresh blood issued from the wound, and the patient's hemoglobin dropped to 7.8 g/dl. Treatment consisted of bedrest, ice packs and transfusions.

A fresh episode of brisk bleeding occurred on April 17 and April 18, decreasing the patient's hemoglobin again to 10.2 g/dl. Surgical exploration was considered but because of the often disappointing results, we considered it wiser to perform arteriography by puncture of the opposite side on April 19. A blush at the site of the lateral circumflex artery was noted (fig. 1). Gelfoam embolization was impracticable due to the long path and multiple curvatures in the catheter. The intima was employed as an embolizing agent after multiple abrasive maneuvers with the guide wire.

Departments of Orthopedic Surgery and Radiology, Stuijvenberg General Hospital, Antwerp, Belgium.

Correspondence and reprints : E. De Groof, Lange Beeldenstraat 267, 2060 Antwerpen, Belgium.

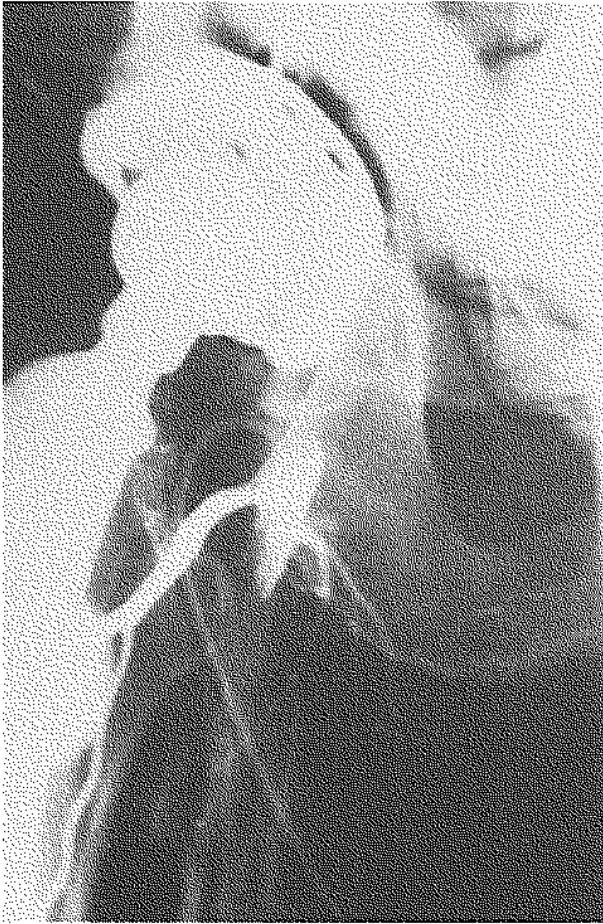


Fig. 1. — Contrast leakage at the injury site on the lateral circumflex artery.

Follow-up arteriography after about 15 minutes showed complete obliteration of the artery (fig. 2). The patient was discharged on May 12, walking with crutches. Some serous fluid was still draining from the wound.

On June 6 he was again admitted with a new episode of fresh bleeding, and his hemoglobin had again decreased to 10.9 g/dl. Arteriography was performed as an emergency but this time by direct puncture of the same side. Bleeding at the same site was encountered. The offending artery was embolized by coils (fig. 3, 4). After one week, the wound was surgically cleaned and closed.

The patient was discharged on June 16 without any further problems.

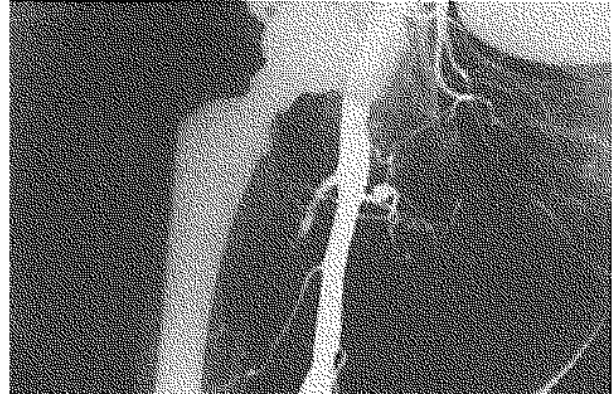


Fig. 2. — After first successful embolization.

DISCUSSION

This case is reported mainly because of its rarity. An injury to the lateral circumflex femoral artery has been reported only twice (10). In both these cases, a false aneurysm was described. We might have had a similar outcome had the lesion not been anatomically delineated by arteriography and eradicated by complete embolization.

The mechanism of injury was probably an arterial tear caused by a Hohmann retractor often placed at the medial side near the lesser trochanter, to obtain medial retraction of the anterolateral thigh muscles, during an (antero)lateral approach (10). Blunt retractors might therefore prevent these lesions (17). However, it seems illogical that this complication is not seen more often despite the worldwide use of the (antero)lateral incision and the routine placement of a Hohmann retractor at the neck of the femur. We therefore suggest that such lesions might be the cause of deep hematomas after THR of so-called "unknown origin". As hematomas are reported to predispose to secondary deep infection (12), which is the greatest enemy of surgeons performing arthroplasties, it might be better to routinely investigate cases with large hematomas by means of arteriography. Because surgical exploration for bleeding is often very disappointing (2) and because the lesions often cannot be reached by surgical means, we prefer arteriography and if possible embolization. This was also suggested by Hopkins (5), Jasty (6), and Lozman (9).

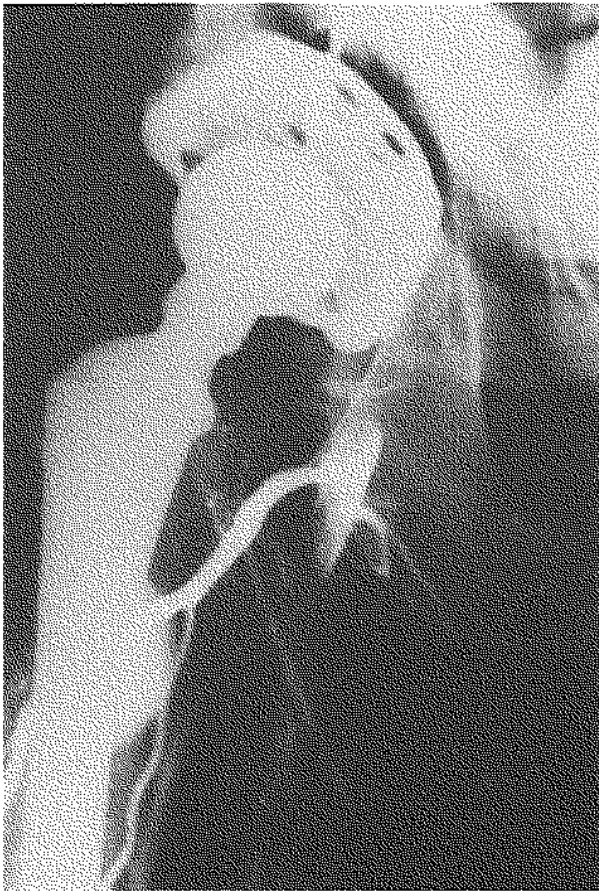

Fig. 3. — New leakage of contrast at the same place.

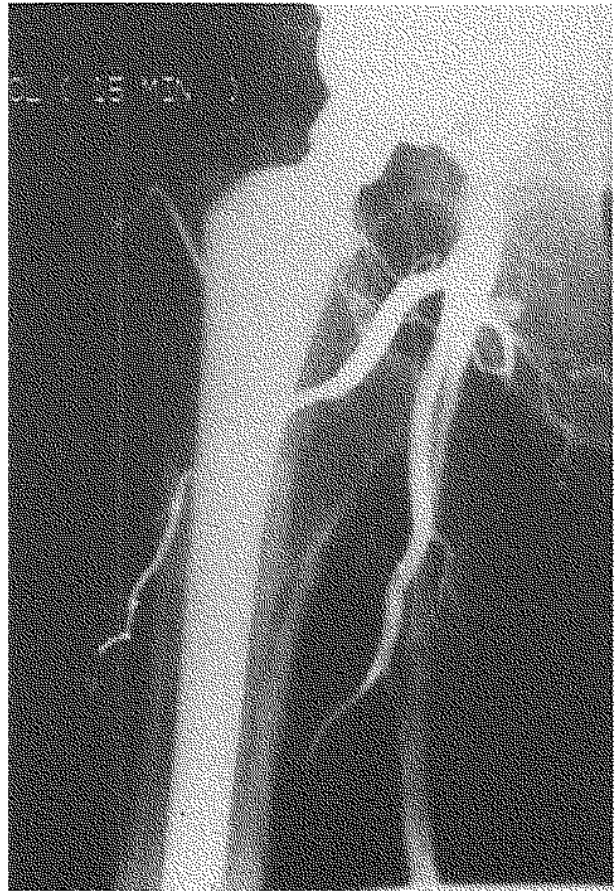

Fig. 4. — New and definitive successful embolization.

CONCLUSION

In conclusion, we suggest that, in the case of large postoperative hematomas, selective arteriography (if possible via direct puncture of the femoral artery on the side of the operated hip) is probably advisable and, if the cause of bleeding is found, embolization should be attempted by a radiologist with vascular interventional experience. This arterial damage might be prevented by the judicious use of a blunt Hohmann retractor.

REFERENCES

1. Amstutz H. C. Complications of total hip replacement. *Clin. Orthop.*, 1970, 72, 123-137.
2. Aust C., Bredenberg D. E., Murray D. G. Mechanisms of arterial injuries associated with total hip replacement. *Arch. Surg.*, 1981, 116, 345-349.
3. Bergqvist D., Carlsson A. S., Ericsson B. F. Vascular complications after total hip arthroplasties. *Acta Orthop. Scand.*, 1983, 54, 157-163.
4. Coventry M. B., Beckenbaugh R. D., Nolan D. R., Ilstrup D. M. Total hip arthroplasties: a study of post-operative course and early complications. *J. Bone Joint Surg.*, 1974, 56-A, 273-284.
5. Hopkins N. F. G., Vanhegan J. A. D., Jamieson C. W. Iliac aneurysm after total hip replacement: surgical management. *J. Bone Joint Surg.*, 1983, 65-B, 359-361.
6. Jasty M., Harris W. H. Salvage total hip reconstruction in patients with major acetabular bone deficiency using structural femoral head allografts. *J. Bone Joint Surg.*, 1990, 72-B, 63-67.
7. Kay N. R. M. Some complications of total hip replacement. *Clin. Orthop.*, 1973, 95, 73-79.
8. Kroesc A., Møllerud A. Traumatic aneurysm of the common femoral artery after hip endoprosthesis: a case report. *Acta Orthop. Scand.*, 1975, 46, 119-122.

9. Lozman H., Robbins H. Injury to the superior gluteal artery as a complication of total hip replacement-arthroplasty: a case report. *J. Bone Joint Surg.*, 1983, 65-A, 268-269.
10. Nachbur B., Meyer R. P., Verkkala K., Zürcher R. The mechanism of severe arterial injury in surgery of the hip joint. *Clin. Orthop.*, 1979, 141, 122-133.
11. Nazarian S., Tisserand P., Brunet C., Müller M. E. Anatomic basis of the transgluteal approach to the hip. *Surg. Radiol. Anat.*, 1987, 9, 27-35.
12. Neal J., Wachtel T. L., Garza O. T., Edwards W. S. Late arterial embolization complicating total hip replacement: a case report. *J. Bone Joint Surg.*, 1979, 61-A, 429-430.
13. Ratliff A. H. C. Vascular and neurologic complications in: Ling, R. S. M., ed. "Complications of total hip replacement" (current problems in orthopaedics), Edinburgh, Churchill Livingstone, 1984, pp. 18-29.
14. Ratliff A. H. C. Arterial injuries after total hip replacement, editorial. *J. Bone Joint Surg.*, 1985, 67-B, 517-519.
15. Stubbs D. H., Dorner D. B., Johnston R. C. Thrombosis of the iliofemoral artery during revision of a total hip replacement. *J. Bone Joint Surg.*, 1986, 68-A, 454-455.
16. Suren E. G., Mellman J. R., Leitz K. H. Gefäßkomplikationen beim alloplastische Hüftgelenkersatz. *Arch. Orthop. Unfallchir.*, 1976, 85, 217-224.
17. Todd B. D., Bintliffe I. W. L. Injury to the external iliac artery during hip arthroplasty for old central dislocation. *J. Arthroplasty*, 1990, 5 (suppl.), 53-55.
18. Vanhegan J. A. D., Sellu D. P., Hopkins N. F. G. Iliac aneurysm in hip arthroplasty: surgical repair. *J. R. Soc. Med.*, 1981, 74, 841-843.

SAMENVATTING

E. DE GROOF, D. VIOLON, P. HERMANS, J. BOGHEMANS. Bloeding t.h.v. de arteria circumflexa lateralis na totale heupprothese, behandeld door embolisatie.

Het geval van een patiënt dewelke een lesie opliep van de arteria circumflexa lateralis t.g.v. de plaatsing van een totale heupprothese wordt voorgesteld. Er wordt gesuggereerd dat dit letsel mogelijk frekwenter oorzaak kan zijn van postoperatieve hematomen dan algemeen wordt aangenomen.

Diagnose en behandeling kunnen tegelijkertijd bekomen worden door selectieve catheterisatie en embolisatie.

Preventie bestaat uit het voorzichtig gebruik van stompe Hohmann retractoren.

RÉSUMÉ

E. DE GROOF, D. VIOLON, P. HERMANS, J. BOGHEMANS. Hémorragie de l'artère circonflexe latérale suite à la mise en place d'une prothèse de hanche; traitement par embolisation.

Les auteurs rapportent l'histoire d'un patient qui a présenté une lésion de l'artère circonflexe latérale suite à la mise en place d'une prothèse totale de hanche. Ils sont d'avis que cette complication peut être plus souvent la cause d'un hématome postopératoire qu'on ne le pense généralement.

Le diagnostic et le traitement peuvent être réalisés d'emblée par cathétérisation sélective et embolisation.

La prévention consiste à utiliser avec précaution l'écarteur d'Hohmann pourvu d'une pointe arrondie.