

# RADIATION THERAPY TO PREVENT HETEROTOPIC OSSIFICATION IN CEMENTLESS TOTAL HIP ARTHROPLASTY

L. LINCLAU<sup>1</sup>, G. DOKTER<sup>1</sup>, J. M. DEBOIS<sup>2</sup>, P. GUTWIRTH<sup>3</sup>

**Heterotopic ossification is the most frequent complication in total hip arthroplasty. In this prospective trial the influence of radiation therapy on heterotopic ossification in cementless total hip arthroplasty was investigated. Radiation therapy reduces the incidence and the degree of heterotopic ossification, especially in hips with a poor preoperative range of motion.**

**Keywords :** cementless ; heterotopic ossification ; hip ; prostheses.

**Mots-clés :** sans ciment ; ossifications hétérotopiques ; prothèses.

---

## INTRODUCTION

The reported incidence of heterotopic ossification varies widely, but is found by most authors to be over 50% with a 20-30% incidence of clinically significant heterotopic ossification (3, 6, 7, 12, 13, 17, 24, 25, 27, 29, 30, 31, 36, 37).

Several risk factors for the development of heterotopic ossification have been described, such as sex and age, preoperative range of motion, the primary disease (hypertrophic osteoarthritis, ankylosing spondylitis), previous hip operations, operative technique and surgical approach (24). Concerning the type of prosthesis, an uncemented femoral component was associated in some way with an increased risk of heterotopic ossification (23).

Different modalities have been tested for the prevention of heterotopic ossification. Prophylaxis with nonsteroidal antiinflammatory drugs : indomethacin (7, 28, 29, 32), diclofenac (38), ibuprofen (11), has been recommended. Nevertheless Cella et al. (7) found that 37% of their patients had

complications or adverse effects that required discontinuation of indomethacin.

Several authors observed that biphosphonates are less effective in the prevention of heterotopic ossification (2, 14, 37). Typically heterotopic ossification will occur after cessation of biphosphonate treatment.

The use of radiation therapy was developed at the Mayo Clinic by Coventry and Scanlon (10). They administered 2,000 cGy in 10 doses of 200 cGy. Ayers et al. (1) and Sylvester et al. (35) decreased the total dose to 1,000 cGy in 5 fractions, with identical results. It seems important however to start radiation therapy a few days after surgery.

In this study we compared the incidence and degree of heterotopic ossification in two analogous groups of patients with totally cementless total hip arthroplasty, with and without radiation therapy.

## MATERIAL AND METHODS

One hundred and fifty-four cementless total hip prostheses of the Zweymüller type (39), inserted between January 1987 and December 1990, as a primary procedure in patients with osteoarthritis of the hip, were included. Sixteen patients had bilateral prostheses implanted during the same period. All cemented or

---

<sup>1</sup> Department of Orthopedics, Eeuwfeestkliniek, Harmoniestraat 68, B-2018 Antwerpen, Belgium.

<sup>2</sup> Department of Radiation Oncology, Eeuwfeestkliniek and Sint Vincentiusziekenhuis, Harmoniestraat 68, B-2018 Antwerpen, Belgium.

<sup>3</sup> Medical Statistics, Department of Vascular Surgery, Eeuwfeestkliniek, Harmoniestraat 68, B-2018 Antwerpen, Belgium.

Correspondence and reprints : L. Linclau.

hybrid prostheses or cementless prostheses other than the Zweymüller were excluded. Patients with previous hip operations, such as revision arthroplasty, and patients with primary diseases which may influence the formation of heterotopic ossification adversely (hyper-trophic osteoarthritis, ankylosing spondylitis), or beneficially (rheumatoid arthritis), were also omitted. Finally, the records of 2 hips with a postoperative fracture due to an accident, 3 with postoperative dislocation and 11 with insufficient data, were eliminated.

All of the operations were performed by the same senior surgical team, using the same routine antero-lateral, transgluteal approach and insertion technique.

The study was prospective but for practical and organizational reasons not randomized. From January 1987 through August 1988 and from August 1989 through January 1990 no prevention for heterotopic ossification was employed. From September 1988 through July 1989 and from February 1990 through December 1990 radiation therapy was applied. A total dose of 1,000 cGy was administered in 5 fractions of 200 cGy starting before the fifth day after surgery.

After radioscopy outlining of the radiation field, the dose was administered with a Cobalt 60 unit, calculated at 5-cm depth. The field dimension was usually 11 × 15 cm including the proximal part of the prosthesis, the trochanter region and acetabulum.

Table I shows comparable distribution of sex and age in both groups.

The diagnosis of heterotopic ossification was primarily made with x rays. Radiographs were obtained immediately after the operation, four months and one year after surgery. Any visible ossification around the area of the hip was graded according to the classification of Brooker et al. (5) (tabl. II).

Statistical analysis was performed using the chi square test (8).

**RESULTS**

Heterotopic ossification was found in 74 (48%) of the 154 hips ; only in 27 (36%) of the 75 hips which had undergone radiation therapy but in 47 (60%) of the 79 hips without irradiation ( $p < 0.005$ ). Severe ossification (Brooker class 3 or 4) occurred in one hip (1.3%) of the 75 irradiated, but in 13 of the 79 hips (16.5%) in the group without irradiation ( $p < 0.005$ ) (table III).

Of the 154 hips, 46 had a preoperative range of motion (ROM)  $\leq 3$ , according to the Harris Hip Score (16), in 32 (70%) women and 14 (30%) men.

Table I

**Material**  
154 cementless hips, type Zweymüller

	hips	women	men	mean age
No radiation	79	54	25	64
Radiation	75	53	22	65

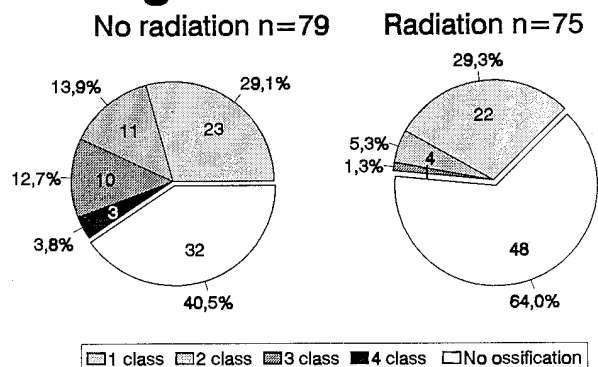
Table II. — Brooker et al., 1973

**Classification of heterotopic ossification**

1. Islands of bone
2. Bone spurs from pelvis and/or femur, with at least 1cm between surfaces
3. Bone spurs from pelvis and/or femur, with less than 1cm between surfaces
4. Bony ankylosis of the hip

Table III. — In all hips (n = 154)

**Degree of ossification**



Twenty-two (48%) of these hips were treated with radiation therapy and 24 (52%) received no prophylactic measures against heterotopic ossification.

In those hips with preoperative ROM  $\leq 3$ , with radiation therapy, 8 hips (36%) developed heterotopic ossification, which is the same percentage as in the other hips with irradiation. Severe ossification was found in 1 hip only (5%). Without irradiation, however, 16 (67%) cases of heterotopic ossification were observed ( $p < 0.05$ ), and 8 (33%) hips had severe class 3 or 4 heterotopic ossification ( $p < 0.025$ ) (tables IV and V).

There are no significant differences in age and sex, between groups in our series.

Table IV. — In hips with preoperative ROM =  $< 3$  (n = 46)

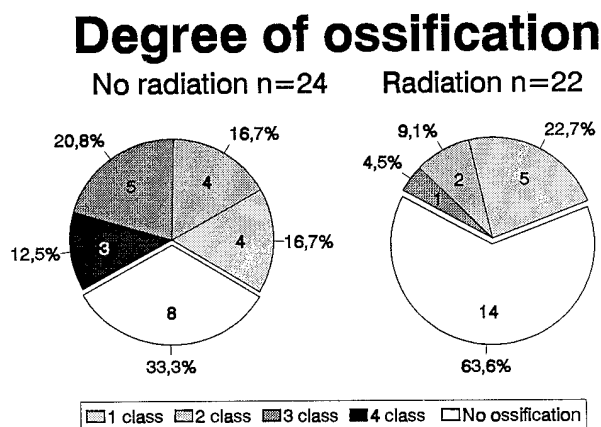
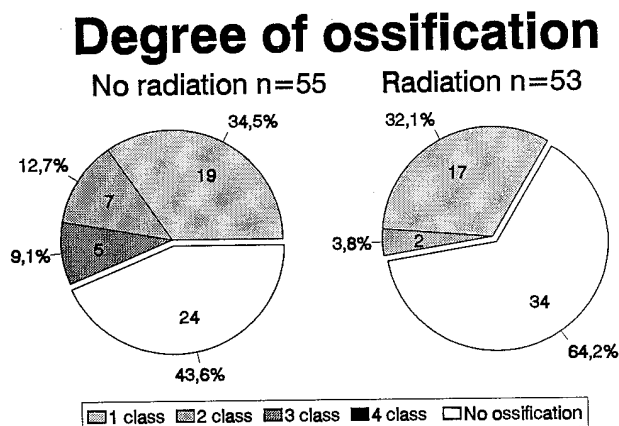


Table V. — In hips with preoperative ROM =  $> 3$  (n = 108)



## DISCUSSION

Cementless fixation depends upon bony ingrowth, or bony apposition, to consolidate the initial fit and stability obtained at surgery. This can be adversely affected by measures used to prevent heterotopic ossification (33). Habermann and his co-workers (15) compared this effect of indomethacin, biphosphonates and radiation therapy.

According to their study, indomethacin administration was not associated with significant inhibition of bony ingrowth. However, other experimental studies have demonstrated that indomethacin may affect bone ingrowth and biological fixation (9, 19, 34). Maloney et al. (23) advise that nonsteroidal antiinflammatory drugs probably should not be used when cementless components have been implanted.

Biphosphonates do prevent mineralization of normal bone, resulting in osteomalacia (26), and Habermann (15) observed no bone ingrowth at all with the oral administration of biphosphonates. These results suggest that the use of biphosphonates should be avoided with cementless fixation.

Although irradiation initially retards the ingrowth of trabeculae into a porous implant for about two weeks, the rate of ingrowth thereafter accelerates. The final level of bony ingrowth appears to be unaffected by the first period of inhibition (15).

Apart from a possible detrimental effect on the healing process of trochanteric osteotomies (35) we found no reports of harmful results of radiation therapy on biological fixation of prostheses. However Sylvester et al. (35) and Maloney et al. (23) recommend the use of external beam radiation with precision shielding of the bone-implant interface in patients who received an uncemented component.

Jasty et al. (18) showed that with doses as low as 1,000 cGy, this method is safe and effective in protecting areas of bone ingrowth from irradiation, while preventing heterotopic ossification elsewhere.

Lo et al. described in 1988 (22) effective prevention of heterotopic ossification with even a single dose of 700 cGy. Therefore since 1992 we have administered one single dose of 750 cGy, before the fifth postoperative day.

Long-term effects of low-dose radiation are not known, but Kim et al. (20) and Brady (4) revealed no radiation-induced sarcomas with doses below 3,000 cGy.

In this study we did not use any shielding of the bone-implant interface and could not find any deleterious effect of radiation therapy, clinically or radiologically, either in general or on the biological fixation of cementless implants, with a follow-up of at least 2 years (21). No trochanteric osteotomies were performed in our series.

### CONCLUSION

Radiation therapy significantly reduced the incidence and the degree of heterotopic ossification after cementless total hip arthroplasty. The use of radiation lowered the incidence of heterotopic ossification from 60% to 36% ( $p < 0.005$ ) and the incidence of severe ossification from 16% to 1% ( $p < 0.005$ ).

In hips with a poor preoperative ROM there is more severe ossification, especially in the absence of radiation therapy. Radiation therapy seems to be most effective in these hips: the incidence of heterotopic ossification decreased from 67% to 36% ( $p < 0.05$ ) and the incidence of severe ossification from 33% to 5% ( $p < 0.025$ ).

### REFERENCES

1. Ayers D. C., Evarts C. M., Parkinson J. R. The prevention of heterotopic ossification in high-risk patients by low-dose radiation therapy after total hip arthroplasty. *J. Bone Joint Surg.*, 1986, 68-A, 1423-1430.
2. Bijvoet O. L. M., Nollen A. J. G., Slooff T. J. J. H., Feith R. Effect of a diphosphonate on paraarticular ossification after total hip replacement. *Acta Orthop. Scand.*, 1974, 45, 926-934.
3. Blasingame J. P., Resnick D., Coutts R. D., Danzig L. A. Extensive spinal osteophytosis as a risk factor for heterotopic bone formation after total hip arthroplasty. *Clin. Orthop.*, 1981, 161, 191-197.
4. Brady L. W. Radiation-induced sarcoma of bone. *Skel. Radiol.*, 1979, 4, 72-78.
5. Brooker A. W. F., Bowerman J. W., Robinson R. A., Riley Jr. L. H. Ectopic ossification following total hip replacement. *J. Bone Joint Surg.*, 1973, 55-A, 1629-1632.
6. Bundrick T. J., Cook D. E., Resnik C. S. Heterotopic bone formation in patients with DISH following total hip replacement. *Radiology*, 1985, 155, 595-597.
7. Cella J. P., Salvati E. A., Sculco T. P. Indomethacin for the prevention of heterotopic ossification following total hip arthroplasty. *J. Arthroplasty*, 1988, 3, 229-234.
8. Conover W. J. Practical nonparametric statistics. New York, Wiley & Sons, 1980, pp. 44-151.
9. Cook S. D. Effects of indomethacin therapies upon biological fixation. Presented at "Total hip replacement, Changing times, what works and what doesn't". 21st Annual Hip Course, Boston, 1991.
10. Coventry M. B., Scanlon P. W. The use of radiation to discourage ectopic bone. A nine-year study in surgery about the hip. *J. Bone Joint Surg.*, 1981, 63-A, 201-208.
11. Elmstedt E., Lindholm T. S., Nilsson O. S., Törnkvist H. Effect of ibuprofen on heterotopic ossification after hip replacement. *Acta Orthop. Scand.*, 1985, 56, 25-27.
12. Errico T. J., Fetto J. F., Waught T. R. Heterotopic ossification. Incidence and relation to trochanteric osteotomy in 100 total hip arthroplasties. *Clin. Orthop.*, 1984, 190, 138-141.
13. Fahrner H., Koch P., Ballmer P., Enzler P., Gerber N. Ectopic ossification following total hip arthroplasty. Is diffuse idiopathic skeletal hyperostosis a risk factor? *Brit. J. Rheum.*, 1988, 27, 187-190.
14. Finerman G. A. M., Stover S. L. Heterotopic ossification following hip replacement or spinal cord injury. Two clinical studies with EHDP. *Metab. Bone Dis. Rel. Res.*, 1981, 4-5, 337-342.
15. Habermann E. T. Panel on radiation and bone ingrowth, presented at "Total hip, Cement versus cementless". Boston, Oct. 4, 1985.
16. Harris W. H. Traumatic arthritis of the hip after dislocation and acetabular fractures. Treatment by mold arthroplasty. An end-result study using a new method of result evaluation. *J. Bone Joint Surg.*, 1969, 51-A, 737-755.
17. Hu H. P., Slooff T. J. J. H., Van Horn J. R. Heterotopic ossification following total hip arthroplasty. A review. *Acta Orthop. Belg.*, 1991, 57, 170-182.
18. Jasty M., Schutzer S., Tepper J., Willett C., Stracher M. A., Harris W. H. Radiation-blocking shields to localize periarticular radiation precisely for prevention of heterotopic bone formation around uncemented total hip arthroplasties. *Clin. Orthop.*, 1990, 257, 138-145.
19. Keller J. C., Trancik T. M., Young F. A., St. Mary E. Effects of indomethacin on bone ingrowth. *J. Orthop. Res.*, 1989, 7, 28-34.
20. Kim J. H., Chu F. C., Woodard H. Q., Melamed M. R., Huros A., Cantin J. Radiation induced soft tissue and bone sarcoma. *Radiology*, 1978, 129, 501-508.
21. Linsau L., Dokter G., Debois J. M., Gutwirth P. The influence of radiation therapy on the Harris Hip Score in cementless total hip arthroplasty. (in preparation).
22. Lo T. C. M., Healy W. L., Cavall D. J., Dotter W. E., Walisewski S. A. Heterotopic bone formation after hip surgery, prevention with single-dose postoperative hip irradiation. *Radiology*, 1988, 168, 851-854.

23. Maloney W. J., Krushell R. J., Jasty M., Hams W. H. Incidence of heterotopic ossification after total hip replacement. Effect of the type of fixation of the femoral component. *J. Bone Joint Surg.*, 1991, 73-A, 191-193.
24. Morrey B. F., Adams R. A., Cabanela M. E. Comparison of heterotopic bone after anterolateral, transtrochanteric and posterior approaches for total hip arthroplasty. *Clin. Orthop.*, 1984, 188, 160-167.
25. Nollen A. J. G., Slooff T. J. J. H. Para-articular ossification after total hip replacement. *Acta Orthop. Scand.*, 1973, 44, 230-241.
26. Ritter M. A., Vaughan R. B. Ectopic ossification after total hip arthroplasty. Predisposing factors, frequency and effect on results. *J. Bone Joint Surg.*, 1977, 59-A, 345-351.
27. Rosendahl S., Krogh Christoffersen J., Norgaard M. Para-articular ossification following hip replacement. *Acta Orthop. Scand.*, 1977, 48, 400-404.
28. Schmidt S. A., Kjaersgaard-Andersen P. Indomethacin inhibits the recurrence of excised ectopic ossification after hip arthroplasty. A 3-4 year follow-up of 8 cases. *Acta Orthop. Scand.*, 1988, 59, 593.
29. Schmidt S. A., Kjaersgaard-Andersen P., Pedersen N. W., Kristensen S. S., Pedersen P., Nielsen J. B. The use of indomethacin to prevent the formation of heterotopic bone after total hip replacement. A randomized, double-blind clinical trial. *J. Bone Joint Surg.*, 1988, 70-A, 834-838.
30. Soballe K., Christensen F., Kristensen S. S. Ectopic bone formation after total hip arthroplasty. *Clin. Orthop.*, 1988, 228, 57-62.
31. Sodemann B., Persson P. E., Nilsson O. S. Periarticular ossification after total hip arthroplasty for primary coxarthrosis. *Clin. Orthop.*, 1988, 237, 150-157.
32. Sodemann B., Persson P. E., Nilsson O. S. Prevention of heterotopic ossification by nonsteroid antiinflammatory drugs after total hip arthroplasty. *Clin. Orthop.*, 1988, 237, 158-163.
33. Stillwell W. T. Heterotopic ossification in total hip arthroplasty. In: *The art of total hip arthroplasty*. 1987, Orlando, Grune & Stratton Inc., pp. 363-370.
34. Sudmann E., Bang G. Indomethacin-induced inhibition of haversian remodelling in rabbits. *Acta Orthop. Scand.*, 1979, 50, 621-627.
35. Sylvester J. E., Greenberg P., Selch M. T., Thomas B. J., Amstutz H. The use of postoperative irradiation for the prevention of heterotopic bone formation after total hip replacement. *Int. J. Rad. Onc. Biol. Phys.*, 1988, 14, 471-476.
36. Testa N. N., Mazur K. U. Heterotopic ossification after direct lateral approach and transtrochanteric approach to the hip. *Orthop. Rev.*, 1988, 17, 965-971.
37. Thomas B. J., Amstutz H. C. Results of the administration of diphosphonate for the prevention of heterotopic ossification after total hip arthroplasty. *J. Bone Joint Surg.*, 1985, 67-A, 400-403.
38. Wahlström O., Risto O., Djerf K., Hammerby S. Heterotopic bone formation prevented by diclofenac. Prospective study of 100 hip arthroplasties. *Acta Orthop. Scand.*, 1988, 62, 419-421.
39. Zweymüller K., Semlitch M. Concept and material properties of a cementless hip prosthesis system with AL203 ceramic ball heads and wrought Ti-6Al-4V stems. *Arch. Orthop. Trauma Surg.*, 1982, 100, 229-236.

### SAMENVATTING

*L. LINCLAU, G. DOKTER, J. M. DEBOIS, P. GUTWIRTH. Radiotherapie ter preventie van peri-articulaire ossificaties bij cementloze totale heup protheses.*

Het optreden van peri-articulaire ossificaties is de meest frequente complicatie bij totale heupprotheses. In deze prospectieve trial wordt de invloed van radiotherapie op het ontstaan van peri-articulaire ossificaties bij cementloze totale heupprotheses onderzocht. Radiotherapie vermindert zowel de incidentie als de graad van peri-articulaire ossificaties, vooral bij heupen met een slechte pre-operatieve functie.

### RÉSUMÉ

*L. LINCLAU, G. DOKTER, J. M. DEBOIS, P. GUTWIRTH. Prévention par la radiothérapie des ossifications périarticulaires après arthroplastie totale de hanche sans ciment.*

Les ossifications périarticulaires sont parmi les complications les plus fréquentes des arthroplasties de hanche. Cette étude prospective s'est donné pour but d'évaluer l'importance de la radiothérapie dans la prévention des ossifications périarticulaires après prothèse totale de hanche sans ciment. La radiothérapie diminue l'incidence et l'importance des ossifications péri-articulaires, surtout pour les hanches avec un important déficit fonctionnel préopératoire.